



## The protective role of ascorbic acid on the testis tissue damage induced by paracetamol in albino rats

[Eda M. Alshailabi](#)<sup>1\*</sup>, [Ola A. Abdalally](#)<sup>2</sup>, [Fatimah A. Mohammed](#)<sup>1</sup>

<sup>1</sup>Zoology Department, Omar Al-Mukhtar University, El Beida, Libya

<sup>2</sup>Almahara institute for the medical and managerial sciences

\*Corresponding Author: [eda.muftah@omu.edu.ly](mailto:eda.muftah@omu.edu.ly)

**Citation:** Alshailabi EM, Abdalally OA, Mohammed FA. The protective role of ascorbic acid on the testis tissue damage induced by paracetamol in albino rats. *Al-Kitab J. Pure Sci.* [Internet]. 2024 Feb 03 [cited 2024 Feb 03];8(1):19-28. Available from: <https://doi.org/10.32441/kjps.08.01.p3>.

**Keywords:** Testis tissues, Ascorbic acid, Histopathology, Paracetamol, Rats.

### Article History

Received	15 Nov. 2023
Accepted	13 Jan. 2024
Available online	03 Feb. 2024

©2021. Al-Kitab University. THIS IS AN OPEN-ACCESS ARTICLE UNDER THE CC BY LICENSE  
<http://creativecommons.org/licenses/by/4.0/>



### Abstract:

Ascorbic acid (AA) plays roles in many biological functions, such as participating in the production of collagen by taking a role in proline and lysine hydroxylation. AA works by removing the reactive oxygen species, thus removing the adhesion of neutrophils to endothelium. The present study investigates the protective effects of AA on the testis tissue damage induced by paracetamol in rats. Thirty-two male rats were equally divided into four groups, with eight rats in each. Group (1) regular control group, group (2) was received 500 mg/kg/b.w. of AA orally for two weeks, group (3) was received 500 mg/kg/b.w. of paracetamol orally for two weeks, group (4) was treated with the AA (500 mg/kg/b.w.) and paracetamol (500 mg/kg/b.w.) orally for two weeks. The histopathological investigations of the testis tissues from the paracetamol group showed atrophy and degeneration of seminiferous tubules with an absence of spermatozoa, presence of cell debris, and loss of the Sertoli cells in some seminiferous tubules when compared with control animals. The testis tissues from a protective group showed less damage in the tubules and germ cells when compared with the paracetamol group. This study indicates that AA protects against paracetamol-induced testis damage in adult male rats.

**Keywords:** Testis tissues, Ascorbic acid, Histopathology, Paracetamol, Rats.

## الدور الوقائي لحمض الأسكوربيك على تلف أنسجة الخصية الناجم عن الباراسيتامول في الجرذان البيضاء

عيدة مفتاح الشيلابي<sup>1\*</sup>، علا علي عبدالعال<sup>2</sup>، فاطمة العماري محمد<sup>1</sup>

<sup>1</sup>قسم علم الحيوان، جامعة عمر المختار، البيضاء، ليبيا.

<sup>2</sup>المعهد اسمه معهد المهارة للعلوم الطبية والإدارية.

[eda.muftah@omu.edu.ly](mailto:eda.muftah@omu.edu.ly), [olaolysweet@gmail.com](mailto:olaolysweet@gmail.com), [fatima.alamari@omu.edu.ly](mailto:fatima.alamari@omu.edu.ly)

### الخلاصة:

يلعب حمض الأسكوربيك أدوارًا مهمة في العديد من الوظائف الحيوية مثل المشاركة في إنتاج الكولاجين من خلال لعب دور في هيدروكسيل البرولين والليسين. يعمل حمض الأسكوربيك على إزالة أنواع الأكسجين التفاعلية عن طريق النقل السريع للإلكترونات في المرحلة المائية، وبالتالي تقليل التصاق العدلات بالبطانة. تبحث الدراسة الحالية في التأثيرات الوقائية لحمض الأسكوربيك على تلف أنسجة الخصية الناجم عن الباراسيتامول في الجرذان. تم تقسيم ٣٢ من ذكور الجرذان بشكل متساوي إلى أربع مجاميع كل منها يحتوي على ثمانية. المجموعة الأولى (المجموعة الضابطة)، المجموعة الثانية تلقت (٥٠٠ مجم / كجم من وزن الجسم) من حمض الأسكوربيك عن طريق الفم لمدة أسبوعين، المجموعة الثالثة تلقت (٥٠٠ مجم / كجم من وزن الجسم) من الباراسيتامول عن طريق الفم لمدة أسبوعين، أما المجموعة الرابعة فقد تلقت حمض الأسكوربيك (٥٠٠ مجم / كجم من وزن الجسم) والباراسيتامول (٥٠٠ مجم / كجم من وزن الجسم) عن طريق الفم لمدة أسبوعين. أظهرت الفحوصات وجود تغيرات نسيجية مرضية في أنسجة الخصية لمجموعة الباراسيتامول كضمور وتنكس في الأنابيب المنوية مع غياب الحيوانات المنوية، ووجود حطام خلوي، وفقدان خلايا سيرتولي في بعض الأنابيب المنوية عند مقارنتها بالحيوانات الضابطة. بينما أظهرت أنسجة الخصية في المجموعة المكونة من حمض الأسكوربيك والباراسيتامول تلعًا أقل للأنابيب والخلايا الجرثومية مقارنة بمجموعة الباراسيتامول. تشير هذه الدراسة إلى أن حمض الأسكوربيك له تأثيرات وقائية ضد تلف الخصية الناجم عن الباراسيتامول في ذكور الجرذان البالغة.

**الكلمات المفتاحية:** أنسجة الخصية، حمض الأسكوربيك، أمراض الأنسجة، الباراسيتامول، الجرذان.

### 1. Introduction:

Antioxidants assist in guarding cells from damage produced by oxidative stress (OS) and improve the body's protection systems against degenerative illnesses. Thus, there is a pressing need to recognize more active and safe antiulcer mediators [1, 2]. The biologically essential antioxidants are vitamins B12, C, and E, giving electrons to free radicals, and the mechanism contains the deduction of initiators of nitrogen species or reactive oxygen [3].

Ascorbic acid (AA) naturally occurs for many biological roles in the body. It is the most antioxidant in plants and is used in agriculture to enhance plant oxidative stress confrontation [4, 5]. AA is an essential antioxidant in extracellular liquid; it protects plasma lipids from

peroxidative damage produced by peroxy radicals [6]. Moreover, AA has the aptitude to counteract free radicals and defend the structure and function of DNA, proteins, and chromosomes against oxidation injury. They are the most influential in reducing the storage and harmfulness of reactive oxygen species (ROS) [7].

Paracetamol (PC) is usually known as acetaminophen. It is a commonly used antipyretic drug and painkilling [8]. PC is processed in the liver by cytochrome P450 (CYP450) enzymes to N-acetyl-benzoquinone imine (NAPQI), where NAPQI reacts with glutathione (GSH). So, the overdoses of PC may lead to a depletion of hepatocellular GSH [9, 2]. PC has an action similar to that of non-steroidal anti-inflammatory drugs (NSAIDs). Likewise, the cyclooxygenase type 2 (COX-2) selective inhibitors are weaker analgesics than NSAIDs or COX-2 selective inhibitors. [10, 11, 12]. Acute overdose of PC could be the reason for the toxicity of testis in men and male animals [13]. Furthermore, the long-term uses of PC cause toxicity effects in the organs, such as the liver, kidney, and testis, and it also affects the blood structures and reproductive hormones. [14,15], such as semen quality, particularly the sperm morphology and fertilizing ability [16]. Moreover, [14, 10] suggested that the long-term of PC caused an increased risk of OS, testicular tubules and blood cell damage, heart infarction, and high blood pressure. The present study investigates the protective effects of AA on the testis tissue damage induced by PC in male albino rats.

## 2. Material and Methods:

**Drugs and chemicals:** Ascorbic acid (AA) ( $C_6H_8O_6$ ) (500 mg) and paracetamol (PC) ( $C_8H_9NO_2$ ) (500 mg) were purchased from the local pharmacy.

**Animals and treatments:** For this study, thirty-two male albino rats (*Rattus norvegicus*) weight 200-250 g were taken from the Central Animal House, College of Veterinary, University of Omar Al-Mokhtar, El-Beida, Libya and were kept in cages at room temperature ( $22 \pm 2^\circ C$ ). Rats were fed with diet and water ad libitum for free intake.

Rats were equally divided into four groups (eight rats):

**Group (1):** In the standard control group (NC), rats were kept under common laboratory conditions as normal control rats with no treatment.

**Group (2):** In the ascorbic acid-treated group (AA), rats were administrated AA at a dose of 500 mg/kg/b.w [17, 18] orally by gavage for two weeks.

**Group (3):** In the Paracetamol-treated group (PC), PC was administered to rats at 500 mg/kg/b.w. [19, 18] orally by gavage for two weeks.

**Group (4):** Protective group (PRO), rats were administered AA at a dose of 500 mg/kg/b.w., then they administered PC at a dose of 500 mg/kg/b.w. Orally by gavage for two weeks.

Rats were given the treatments six days a week [18], and at the end of the study, rats were sacrificed, and then the testes were detached.

### **Histopathological preparation:**

Testis tissue samples were washed in normal saline, fixed in the buffered formalin (10%) for general histological examination, and studied under a light microscope [20]. The changes in the histopathological of the testis tissues were classified as follows: (-) shows regular, (+) shows mild, (++) shows moderate, and (+++) shows severe changes [21, 22].

### **3. Results:**

The result of this research showed a typical structure of the seminiferous tubules in the testis tissues of the standard control group (Figure 1), where the seminiferous tubules had normal spermatogenic cells and Sertoli cells, and everyday interstitial spaces had normal Leydig cells (Figure 2). On the other hand, the testis tissues in the AA group revealed a standard histological structure, such as normal seminiferous tubules (Figure 3), having normal spermatogonial cells and Sertoli cells, as well as everyday interstitial spaces with normal cells of Leydig (Figure 4) as similar is the standard control group.

Whereas, histological examination of the testis section in the treated rats with PC showed different histopathological variations when compared with the standard control group, such as atrophy degeneration and necrosis of spermatogonial cells lining seminiferous tubules, with reduced diameter of seminiferous tubules as well as sloughing of germinal epithelium, congestion in testicular vessel. In addition, some tubules showed a marked reduction in the thickness of the germinal epithelium with loss of sperms in their lumen and focal tubular necrosis (Figure 5). Additionally, (Figure 6) showed that testicular atrophy degeneration appeared in most seminiferous tubules with fewer sperms in their lumen, and irregularly organized sperm cells with distortions of sperm cells as well as sloughing of germinal epithelium, degenerative changes like vacuoles of the interstitial tissue. So, the testis of the male adult rats, when given the PC at two weeks, showed severe damage in the testicular tissues.

Nevertheless, the testis sections of rats treated in the PRO group for two weeks showed minor damage in the testis tubules and germ cells compared to the PC group. Improve testicular arrangement with normal spermatozoa in their lumen, normal seminiferous epithelium with spermatogonia, reorganization of the germinal cells layer with some seminiferous tubules have a few intraepithelial empty spaces, normal Sertoli cells are seen with attached sperms, interstitial spaces were within a standard limit, and Leydig cells these were apparent in the (Figure 7, 8). Finally, in many parts of the testis tissues in PRO rats, they showed almost normal structures.



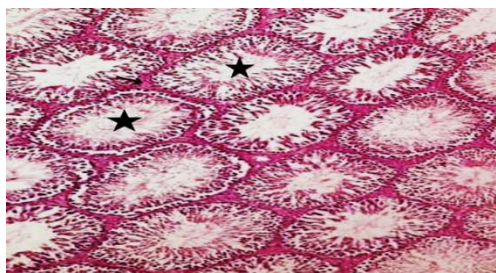


Figure 1: Microscopic image of the testis section of NC rats showing normal seminiferous tubules (stars). (H & E stain, X100).

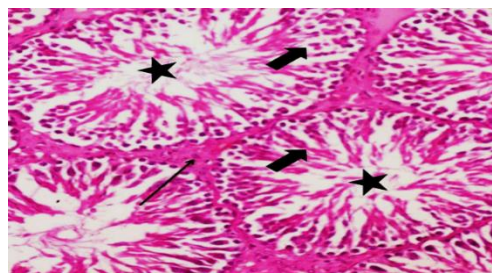


Figure 2: Microscopic image of the testis section of NC rats showing normal seminiferous tubule with standard germinal cell layer (thick arrow), spermatozoa (stars), and normal Leydig cells (arrow) (H & E, X400).

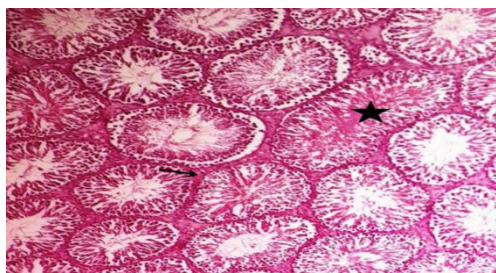


Figure 3: Microscopic image of the testis section of AA rats showing normal seminiferous tubules (star) and standard interstitial spaces (arrow). (H & E stain, X100).

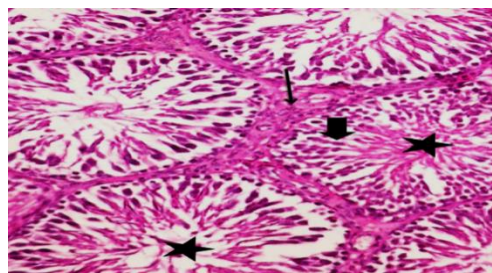


Figure 4: Microscopic image of the testis section of AA rats showing normal seminiferous tubule with standard germinal cell layer (thick arrow), sperms (stars), and everyday interstitial spaces with normal Leydig cells (arrow) (H & E, X400).

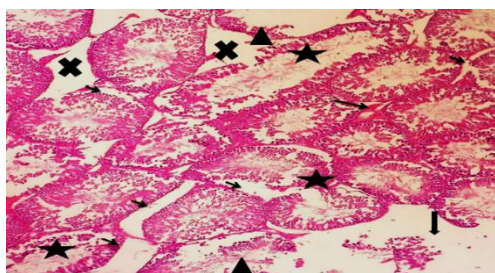


Figure 5: Microscopic image of the testis section of PC rats showing atrophy degeneration and necrosis of spermatogonial cells lining seminiferous tubules, with reduced diameter of seminiferous tubules (stars), widening of the interstitial tissue (X), as well as sloughing of germinal epithelium (small arrows), congestion in testicular vessel (thin arrows). Some tubules show a marked reduction in the thickness of the germinal epithelium with loss of sperms (head arrows) and focal tubular necrosis (thick arrows). (H & E, X100).

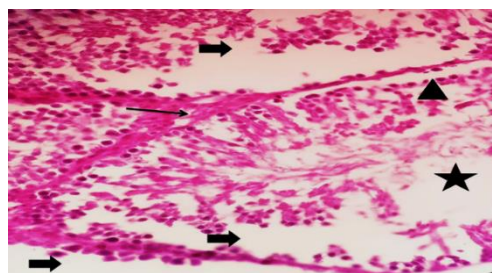


Figure 6: Microscopic image of the testis section of PC rats showing atrophy degeneration of the seminiferous epithelium (arrows) with fewer sperms in the lumen (stars) and irregularly organized sperm cells with alterations of sperm cells (head arrows) as well as sloughing of germinal epithelium (thick arrows), degenerative changes like vacuoles of the interstitial tissue (long arrow). (H & E, X400).

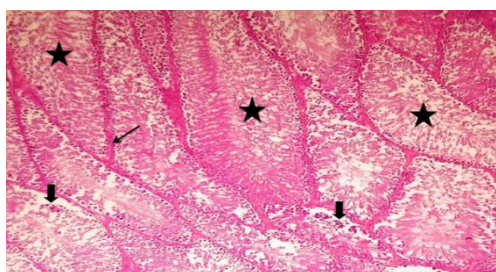


Figure 6: Microscopic image of the testis section of PRO rats showing improved testicular arrangement with normal tubules and germinal cells, repair of some seminiferous tubules with a few intraepithelial empty spaces (thick arrows), normal sperms in the lumen (stars), and standard interstitial spaces within normal Leydig cells (arrow) (H & E, X100).

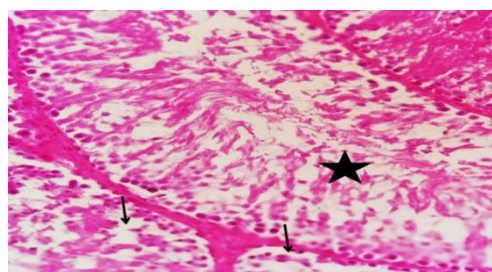


Figure 7: Microscopic image of the testis section of PRO rats showing normal spermatozoa in their lumen (star), seminiferous epithelium with spermatogonia (thick arrow), repair of some seminiferous tubules with a few intraepithelial empty spaces and reorganization of germinal cell layer (arrows). (H & E, X400).

### Histopathological variations:

The histopathological variations of the testis tissues are given in (**Table. 1**). The testis tissues of the PRO rats showed a significant improvement in their tissue structure when compared with the PC group.

**Table 1: Incidence of histopathological changes in the testis tissues in the normal control and experimental groups.**

organs	Lesions	NC	AA	PC	PRO
Testis Tissues	Degeneration of seminiferous tubules	-	-	+++	-
	Widening of the interstitial tissue	-	-	++	-
	Reduction of spermatozoa	-	-	++	-
	Necrosis	-	-	++	-
	Absence of spermatogenesis	-	-	++	-
	Degeneration of germinal cells	-	-	+++	+
	Vacuolations	-	-	++	-
	Reduction of Sertoli cells	-	-	++	-
	Atrophy of seminiferous tubules	-	-	+++	-
	Absence of the spermatozoa	-	-	++	-
	Reduction of Leydig cells	-	-	++	-

\*(-) shows normal, (+) shows mild, (++) shows moderate, (+++) shows severe changes.

\*NC is the standard control group, AA is the ascorbic acid group, PC is the paracetamol group, and PRO is protective.

## 4. Discussion:

Results obtained in the present study showed histopathological changes in treated rats with PC for two weeks when compared with the NC rats, such as atrophy degeneration and necrosis of spermatogonial cells lining seminiferous tubules, with a reduced diameter of seminiferous tubules as well as a marked reduction in the thickness of the germinal epithelium with loss of sperms in their lumen, and irregularly arranged sperm cells with distortions of sperm cells as well as sloughing of germinal epithelium, degenerative changes like vacuoles of the interstitial tissue which is in agreement with other studies [23], who found that the taken of the PC showed many histopathological variations in testes rats. They said that giving PC to the male rats' gnawers is mainly due to testicular degeneration and difficulty of spermatogenesis—these effects on the testis by prostaglandins on male maturity and spermatogenesis [24]. Moreover, the PC may cause impaired fertility by testicular toxicity. Also, the toxic effects of an overdose of PC on the reproductive organs of male animals may induce several changes and damagingly affect the tissue structure of the testis tubules [25, 26, 13]. So, the results showed that the PC

can potentially cause reproductive toxicity when high and long-term treatment. Research by [27] indicates that high doses of PC lead to unwanted side effects, such as the production of ROS that leads to OS. Furthermore, ROS may similarly affect the Sertoli cells, which impacts the protein mixture hardware required to depart the germ cells [28]. Besides that, the PC could pervade the blood of the testis barrier with alteration in the microenvironment of the seminiferous tubules, thus creating a different microenvironment in the testicular functions and the barrier of the seminiferous tubules [29].

Meanwhile, the testis tissues of the POR rats showed improved testicular structure with normal spermatozoa, seminiferous tubules, and typical structures of the Leydig cells compared to the PC group. AA protects against PC by removing the OS and reducing cell apoptosis [30, 31]. Moreover, it has been reported that AA inhibited OS. It reduced the lipid products and protein peroxidation [31]. Also, Heikal 2014 showed the protective properties of the AA in lowering the levels of biochemical changes and histopathological assessments.

Moreover, histopathological variations of the testis tissues in the albino rats showed that the AA was protective against PC-induced testis injury.

## 5. Conclusion:

The present results determine that histopathological variations in the testis tissues of the albino rats cause PC. In addition, the AA has protective roles against PC-induced testis injury in male rats.

## 6. References:

- [1] De Lira Mota KS, Dias GEN, Pinto MEF, Luiz-Ferreira A, Souza-Brito ARM, Hiruma-Lima CA, Barbosa-Filho JM, Batista LM. Flavonoids with gastroprotective activity. *Mole*. 2009 Mar; 14(3): 979-1012. <https://doi.org/10.3390/molecules14030979>.
- [2] Alshailabi EMA. The protective effects of indole-3-carbinol on stomach injury in rats. *L J B S*. 2021 Jul; 14 (1): 12-24. <https://doi.org/10.36811/ljbs.2021.110070>.
- [3] Abdulkhaleq FM, Alhussainy TM, Badr MM, Khalil AA, Gammoh O, Ghanim BY, Qinna A. N. Antioxidative stress effects of vitamins C, E, and B12, and their combination can protect the liver against acetaminophen-induced hepatotoxicity in rats. *Drug Des Devel Ther*. 2018 Oct;18(12): 3525-3533. <https://doi.org/10.2147/DDDT.S172487>.
- [4] Johnson M, Olufunmilayo LA, Anthony DO, Olusoji EO. Hepatoprotective effect of ethanolic leaf extract of *Vernonia amygdalina* and *Azadirachta indica* against acetaminophen-induced hepatotoxicity in Sprague-Dawley male albino rats. *American J Pharmacol Sci*. 2015Jul; 3(3): 79-86. <https://doi.org/10.12691/ajps-3-3-5>.
- [5] Hassanin KMA, Hashem KSH, Samraa H, Abdel-Kawi SH. Hepatoprotective effects of vitamin C and micronized vitamin C against paracetamol induced hepatotoxicity in rats: A



- comparative study. *Int J Biochem Biotechnol.* 2017 Jan; 6(4): 756-766. <https://doi.org/10.21608/JVMR.2013.77678>.
- [6] Matić MM, Milošević MD, Paunović MG, Ognjanović BI, Štajn AS, Saičić ZS. Paracetamol-induced changes of haematobiochemical and oxidative stress parameters in rat blood: Protective role of vitamin C and  $\beta$ -glucan. *Kragujevac J. Sci.* 2016 Mar; 38:135-146. <https://doi.org/10.1080/01480545.2019.158745>.
- [7] Al-Eryani MAY, Shediwah FMH, Al-Awar MSA, Salih EMA, AL- Shaibani EAS. The ability of vitamin A, alone or in combination with vitamins C and E, in ameliorating the side effects of penicillin and streptomycin on hepatic damage in guinea pigs. *JJBS.* 2014 Jun; 7(2): 127-132. <https://doi.org/10.12816/0008226>.
- [8] Olatosin TM, Akinduko DS, Uche CZ, Bardi J. Effects of *Moringa oleifera* seed oil on acetaminophen-induced oxidative stress and liver damage in Wistar albino rats. *IOSR-JPBS.* 2014 Jan; 9(2):53-59. <https://doi.org/10.9790/3008-09215359>.
- [9] Blessing O, Frederick O. Effects of concurrent administration of paracetamol and aqueous extract of *Hibiscus sabdariffa* Linn calyx on paracetamol hepatotoxicity in Mice. *J. Pharm Chem Biol Sci.* 2017 Aug; 5(2):108-117.
- [10] Ottani A, Leone S, Sandrini M, Ferrari A, Bertolini A. The analgesic activity of paracetamol is prevented by the blockade of cannabinoid CB1 receptors. *Eur J Pharmacol.* 2006 Feb; 15 (1-3):280-281. <https://doi.org/10.1016/j.ejphar.2005.12.015>.
- [11] Graham GG, Davies MJ, Day RO, Mohamudally A, Scott KF. The modern pharmacology of paracetamol: Therapeutic actions, mechanism of action, metabolism, toxicity and recent pharmacological findings. *Inflammopharmacol.* 2013 Jun; 21(3):201-32. <https://doi.org/10.1007/s10787-013-0172-x>.
- [12] Józwiak-Bebenista M, Nowak JZ. Paracetamol: Mechanism of action, applications and safety concern. *Acta Pol Pharm.* 2014 Feb; 71(1):11-23.
- [13] Mohammed HU, Sabry RM. The possible role of curcumin against changes caused by paracetamol in testis of adult albino rat (histological, immunohistochemical and biochemical study). *EJH.* 2020 Sep; 43(3): 819-834. <https://doi.org/10.21608/ejh.2019.18599.1189>.
- [14] Olaleye MT, Rocha BTJ. Acetaminophen induced liver damage in mice: Effect of some medicinal plants on the oxidative defense system. *Exp Toxicol Pathol.* 2008 Mar; 59(5):319-27. <https://doi.org/10.1016/j.etp.2007.10.003>.
- [15] Khayyat LI. Evaluate of the efficacy of extra *Virgin* olive oil against paracetamol overdose induced renal toxicity in albino rats. *Umm Al-Qura Univ J App Sci.* 2018 Jun; 5(1): 1-13. <https://doi.org/10.5053/ejobios.2016.10.0.4>.
- [16] Khayyat LI. Extra *Virgin* olive oil protects the testis and blood from the toxicity of paracetamol (overdose) in adult male rats. *Biol.* 2021 Oct; 10: 1-14. <https://doi.org/10.3390/biology10101042>.
- [17] Adeneye AA, Olagunju JO. Protective effect of oral ascorbic acid (vitamin C) against acetaminophen-induced hepatic injury in rats. *Afr. J. Biomed. Res.* 2008 Ma; 11: 183-190. <https://doi.org/10.4314/ajbr.v11i2.50704>.



- [18] Abdalally OA, Alshailabi, EMA, Ali MS. Effects of vitamin C on liver and kidney enzymes and some biochemical parameters against paracetamol induced hepato-nephrotoxicity in rats. *Sirte U Sci J (Applied Sci.)*. 2021 Dec; 12(2): 59-72.
- [19] Modo E, Okwandu N, Dongo B. Comparative effects of vitamin C and vitamin E pre-treatment in acute paracetamol induced toxicity on the liver of rats. *World J Pharm Sc*. 2015 Feb; 3(3): 407-412.
- [20] Lillie RD. *Histopathological techniques and practical histochemistry*. Mc Graw-Hill U.S.A. 1954.
- [21] Moshai-Nezhad P, Bahari Z, Jangravi Z, Zarei SM, Iman MJ. The effect of *Descurainia sophia* seed extract on nephrotoxicity markers induced by acetaminophen in mice. *J Adv Med Biomed Res*. 2021 Apr; 29(134):139-144. <https://doi.org/10.30699/jambs.29.134.139>.
- [22] Alshailabi EMA, Al- Zail NI, Abraheem RA. The effects of cigarette smoke on the epididymal tissues in adult male albino rats and the ameliorative effect of the Sidr honey. *Libyan J Med Res*. 2023 Ma; 16 (2B): 79-92.
- [23] Haroun MR, Eldin AA, EL-Khouly SM, Mostafa IA. The protective effect of ascorbic acid and curcumin on the chronic toxicity of meloxicam on the testis of adult albino rats. *BJAS*. 2020 Aug; 5(5):189-207. <https://doi.org/10.21608/bjas.2020.136691>.
- [24] Uzun B, Atli O, Perk BO. Evaluation of the reproductive toxicity of naproxen sodium and meloxicam in male rats. *HET*. 2015 Jul; 34(4):415-429. <https://doi.org/10.1177/0960327114542886>.
- [25] Luangpirom A, Kourchampa W, Junaimuang T. Attenuating effect of *Allium ascalonicum* L. on paracetamol induced seminal quality impairment in mice. *JMPR*. 2012 Apr; 6: 2655–2659. <https://doi.org/10.5897/JMPR11.1602>.
- [26] El-Maddawy ZK, El-Sayed YS. Comparative analysis of the protective effects of curcumin and N-acetyl cysteine against paracetamol-induced hepatic, renal, and testicular toxicity in Wistar rats. *Environ Sci Pollut Res Int*. 2018 Feb; 25(4):3468-3479. <https://doi.org/10.1007/s11356-017-0750-3>.
- [27] James LP, Mayeux PR, Hinson JA. Acetaminophen-induced hepatotoxicity. *Drug Metab Dispos*. 2003 Dec; 31(12):1499-506. <https://doi.org/10.1124/dmd.31.12.1499>.
- [28] Karaguzel E, Kadihasanoglu M, Kutlu O. Mechanisms of testicular torsion and potential protective agents. *Nat Rev Urol*. 2014 Jul; 11(7):391-399. <https://doi.org/10.1038/nrurol.2014.135>.
- [29] Olaniyi KS, Agunbiade TB.  $\alpha$ -tocopherol attenuates acetaminophen-induced testicular dysfunction in adult male rats. *Int J Health Allied Sci*. 2018, 7(1):6-11. <https://doi.org/10.4103/ijhas.IJHAS-100-17>.
- [30] Ghorbani-Taherdehi F, Nikravesh MR, Jalali M, Fazel AR, Gorji Valokola M. Evaluation of the antioxidant effect of ascorbic acid on apoptosis and proliferation of germinal epithelium cells of rat testis following malathion-induced toxicity. *Iran J Basic Med Sci*. 2020 Ma; 23:569-575. <https://doi.org/10.22038/ijbms.2020.35952.8608>.

- [31] Mohamed M, Mohamed A, Eldeen EA. The possible protective effect of vitamin C against sildenafil citrate affected liver of adult and senile male albino rats (Light and Electron Microscopic Study). AIMJ. 2022 Oct; 3(10): 8-14. <https://doi.org/10.21608/aimj.2022.143240.1974>.
- [32] Heikal TM, Mossa ATH, Khalil WKB. Protective effects of vitamin C against methomyl-induced injures on the testicular antioxidant status and apoptosis-related gene expression in rat. J Environ Anal Toxicol. 2014 Mar; 5(2) 1-7: e1000255. <https://doi.org/10.4172/2161-0525.1000255>.