

Comparison of CD19, CD8 and FOXP3 Expression among Hydatid Human Liver Infection

¹Atyaf ali Kadim Al-asadi, ²Dhamiaa M. Hamza, ³Sawsan M.Jabbar Al-Hasnawi

¹MCs student, ²Assistant prof, ³MBChB, MSc & PhD

^{1,2} Medical microbiology Department Kerbala University

³Clinical immunology/medical Microbiology Department Kerbala University

***Corresponding Author:**

Dhamiaa makki Hamza (Asst. Professor)

Department of Medical Microbiology College of Medicine /University of Kerbala, Kerbala-Iraq

Type of Publication: Original Research Paper

Conflicts of Interest: Nil

ABSTRACT

Background: Cystic echinococcosis is a parasitic zoonosis that causes significant economic losses and poses a threat to public health, is caused by larvae of the tapeworm *Echinococcus granulosus* the aim of this study was to quantification of protein expression of CD markers (cd8, cd19, foxp3) with hepatic infection with hydatid cyst in human by image j technique and compare immune response between each other for these biomarker use immunohistochemistry technique (IHC). METHOD: One- hundred blocks collected from Al Hussein Teaching Hospital and Noor alhussain medical laboratory .Control group blocks were collected from unit of forensic medicine at Al-Hussein Teaching Hospital, in Th-Qar, Iraq. RESULT: (IHC)where performed on CD markers(cd8,cd19,foxp3), the result was show CD19 monoclonal antibody expression was the predominant marker increase compared to other marker ,The CD8and FOXP3corresponds to T-Cell and T-Reg, that the mean expression of CD8 comes after CD19expression and followed byFOXP3.Although the immune expression of Foxp3 in the disease group show the most lower expression For conclusion different immune cell showed to be involved in local response to humane hydatid cyst. in addition for the significant higher of expression of CD19 which suggest important role of B-cell in that site.

Keywords: NIL

INTRODUCTION

Cystic echinococcosis also known as “hydatid disease” is a zoonotic infection caused by the *Echinococcus* tapeworm at its larval stage (metacestode). It is one of the seventeen neglected tropical diseases (NTDs) identified by World Health Organization (WHO). The main specie causing cystic echinococcosis is *E. granulosus*. Single organ is involved in up to 80% patients with cyst localized to lungs (1/5) or liver (4/5).(Brunetti et al., 2010)

Echinococcus granulosus is a parasite also called hydatid worm or tapeworm, belongs to the phylum Platyhelminthes and class Cestode. The length of

adult *E. granulosus* is 3-6 mm. Its life cycle starts from the definitive hosts, such as canids and dogs, and then continues in the intermediate hosts like human. Its larvae evolve as discrete single cyst which is less severe and treatable. Nevertheless, multiple and large cysts cause irreversible destruction to the organ. (Moro and Schantz, 2009).

The hydatid cyst occurs more frequently in liver. About 60-70% cases with liver hydatosis has been seen. Liver is first effective filter of body so it as at higher risk of getting infected by the parasite.(Bektas et al., 2016) The cyst in liver grows silently and

remains asymptomatic for several years. The infection is progressive slowly due to which symptoms and complications may arise.(Chautems et al., 2003)If eggs pass the liver then they reside in the lungs. About 15% cases alveolar echinococcosis have been reported. *E. granulosus* can affect some other organs as well such as kidney, brain, spleen, skin, skeletal system, muscle (8% of all cases in total).(Zheng et al., 2015) .

The diagnosis of CE at early stages is often incidental due to its asymptomatic nature. The non-invasive diagnostic technique involves immunodiagnosis and radiologic imaging diagnosis.(Nunnari et al., 2012) Immunohistochemistry (IHC) is a significant application of polyclonal as well as monoclonal antibodies to check the tissue distribution of a specific antigen in disease and health. IHC is mainly used to diagnose a wide span of diseases such as cancer, cysts, tumors etc.(Ruangpratheep et al., 2017) IHC involves highly specific antigen-antibody reactions. In case of hydatid cysts IHC is performed by using anti-human CD19 (Cluster of differentiation19), CD8(Cluster of differentiation18) and Foxp3 (fork head box P3) antibodies.(Jafari et al., 2019).

CD8 cells are also known as memory T cells that recognize the foreign body at first time of infection and then protect the body of host from the same foreign body in the time of re-infection. CD8 can be classified into two subsets; Effector (TEM) and Central (TCM). But their relationship and ability to confer and persist protective immunity are not well understood. Some results have shown that TCM possesses greater capacity as compare to TEM.(Wherry et al., 2003).

A 95 kD transmembrane glycoprotein, CD19 human antigen, belongs to the immunoglobulin superfamily. CD19 works as dominant signaling element of multimolecular complex on mature B cells' surface, with the help of complement receptor CD21, tetraspanin membrane protein CD81 (Cluster of differentiation 81)(TAPA-1)(Target of the Antiproliferative Antibody 1)and CD225(Cluster of differentiation 225).(Wang et al., 2012).

Human FOXP3 is a member of winged-helix or fork-head family of transcription factors. Some studies have shown that FOXP3 is master regulatory gene for the function of CD25+ CD4+ Treg cells and cell

lineage commitment. (Wisse et al., 1996) Whereas some studies showed that FOXP3 expression in T cells is not necessarily linked with immune regulation.(Gavin et al., 2006)

The local immune response against CE in humans is barely known, especially related to the lymphocyte subtypes involved in. Studies on human subject gives only single point observations due to which we don't know much about immune response variations within humans. (Jafari et al., 2019).

Materials & methods

The type of the study is retrospective case control study. One- hundred sample (block) collected (50 cases and 50 control group). Samples of hydatid cyst and surrounding tissue of liver were collected from Al-Hussein Teaching Hospital, Noor alhussain medical laboratory and Ibn al-Bitar clinical Laboratory .Control group were collected from unit of forensic medicine at Al-Hussein Teaching Hospital, in Th-Qar, Iraq. the samples were collected during the period from November 2018 through January 2019 . hydatid patients age ranged between 15 to 85 years old, also the gender revealed that a higher prevalence of hydatid in female, in which the percentage of female was 66%, whereas it was 34% male. This study of The (IHC) staining procedure and Histopathology was conducted in the histopathology laboratory of the Al-Hussein Teaching Hospital.

Immunohistochemical staining procedure

1-Cutting and sectioning 3-4 thickness of formalin-fixed paraffin-embedded tissues on slides charged with positive charged. . Then Air dry at 58° C for 2 hours.

2-Deparaffinizing slides through three change of xylene, incubating slide 10 min in each change.

3-Dehydrating the cross section slide by using A series change of alcohol from 70% to 100% and rehydrate tissues.

4-placement the slide in microwave to heat epitope retrieval cover the slide with Immuno DNA Retriever (retrieval solution) with EDTA (BSB 0030-BSB 0033) or Citrate (BSB 0020-BSB 0023).

5-continuing microwaving at 80% power for 12 minutes and then cooling for minimum of 30 minutes.

6-Washing with 3 changes for 2minute each change by using Immunohistochemical Washing buffer and Placing a positive charge slides in (PolyDetector Peroxidase Blocker) for 5 min. Drying excess PBS from slide and circled the tissue by Dako pen.

7-Washing with 3 changes for 2 minute by Immunohistochemical Washing buffer, Covering tissue with the Primary Antibody following manufacturer’s recommended protocol. If using concentrated antibodies, we suggest using our ImmunoDetector Protein Blocker/Antibody Diluent to incubate the tissue slide for 45min, after covering with PolyDetector HRP Label.

8-Rinsing with 3 changes of Immunohistochemical washing buffer Preparing DAB solution by adding each per mL of PolyDetector DAB Buffer, one drop of PolyDetector DAB Chromogen and then mix.

9-Covering tissue with prepared DAB substrate-chromogen solution, incubate for 10 min Covering tissue with prepared DAB substrate-chromogen solution, incubate for 10 min and Rinsing with 5 changing of Distil water then Countering stain and finely dehydrated finally putting Cover slip and Observing under microscope.

Result

Study was conducted on 100 blocks control group and patient, classification of hydatid liver cases in to acute and chronic. The comparison between acute and chronic depended on inflammatory cell and histopathology changes and size of cyst in cases infection with hydatid cyst use (IHC).Result show significant differences also the correlation between CD8and FOXP3 depended on protein expiration. The result show CD8 marker found to be a negatively correlated with foxp3 of hydatid cases but no significantly differences but the correlation between CD19 and CD8 depended on protein expiration. The result show CD19 marker found to be a positive correlation with CD8 of hydatid cases but no significantly differences, the comparison between CD19, CD8 and FOXP3 depended on immune (protein) expiration among hydatid liver infection group, result show CD19 marker found to be significant high than other biomarker expression, followed by CD8 and lower of them is FOXP3 ,that show lower than control group.

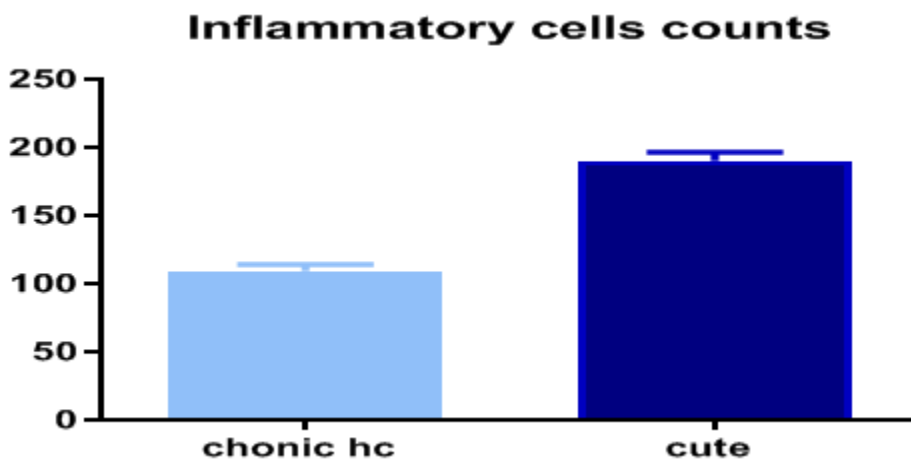


Figure 1: Bar chart show classification of hydatid liver cases in to acute and chronic

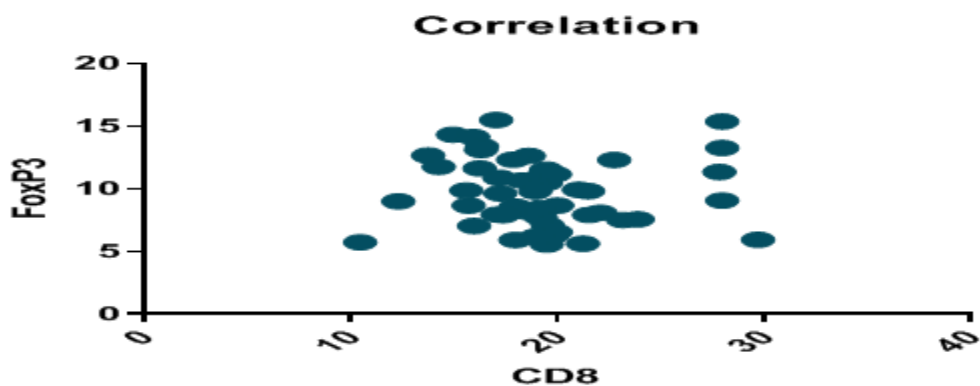


Figure 2: Scatter plot of correlation between CD8 and FOXP3 depended on protein expiration

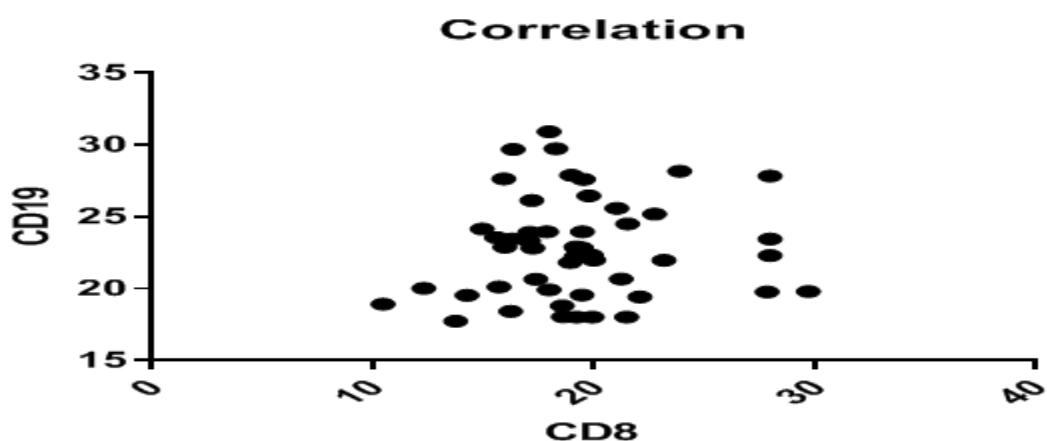


Figure 3: Scatter plot of correlation between CD19 and CD8 depended on protein expiration

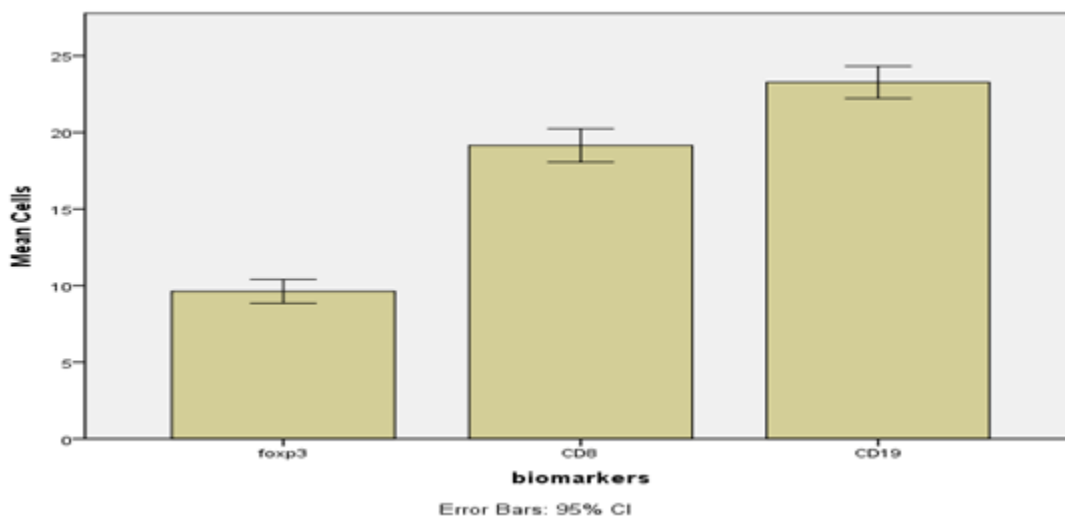
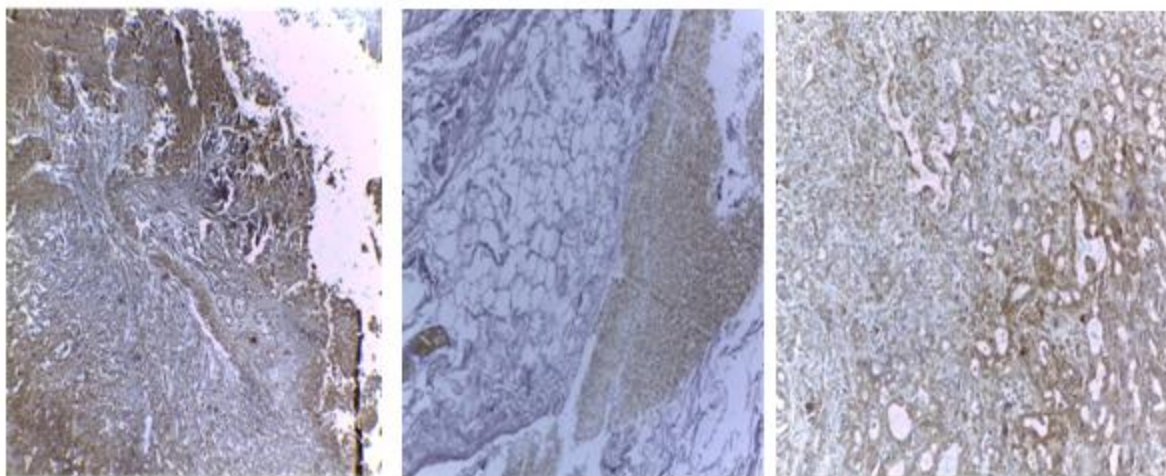


Figure 4: Bar chart show comparison of CD19, CD8 and FOXP3 among hydatid liver infection groups



Picture: Immunohistochemical expression of the CD8, FOXP3 (low power10x) and CD19 marker (low power40x), in the liver of cases with hydatid cyst, the image show a thick fibrous layer separates the parasite from the host parenchyma.

Discussion

In this study all of the samples stained with H&E showed a significant increase in inflammatory cell. the result of current study of this classification show a significant different with more acute cases of hydatid liver infection .These result suggest a marked participation by T cells in the infiltration of eosinophils and other inflammatory cell due to immune reaction in the pericystic adventitia layer. Conclude that the immune lymphatic system and eosinophils are primarily involved in the formation of progressive and regressive hydatid lesions and lead to this classify depending on it , this finding is similar to(Sakamoto and Cabrera, 2003) study.

In the study of correlation between CD8and FOXP3 depended on immunoexpression of this marker. The result show CD8 marker found to be a negative correlation with immunoexpression of foxp3 of hydatid liver cases but no significantly differences. This finding was not in agreement with ((Jafari et al., 2019)), who explained that Foxp3+Tregs were significantly and positively correlated with the numbers of CD8+CTL.

In our present study of correlation between CD19 and CD8 depended on immune expression of this pair marker. The result show CD19 marker found to be a positive correlation with CD8 of hydatid cases but no significantly differences. This finding was not in agreement with (Chen et al., 2019) who explain the Breg cell percentage was negatively correlated with CD8+ T cells in cervical cancer patients. also not in

agreement with (Bossowski et al., 2003)who explain that in the untreated Graves' patients we observed an increase in the percentage of CD19+ and a decrease in the percentage of CD8+ cells in comparison to the healthy control subjects and thyroid Graves' patients and that mean negatively correlated between each other of this pair marker.

The comparison between CD19,CD8and FOXP3 depended on immune (protein) expression among hydatid liver infection group. The result show CD19 marker found to be significantly high than other biomarker expression in liver infection group ,followed by CD8 and lower of them is FOXP3 ,that biomarker show lower than control group. This finding was not in agreement with (MONTALLI et al., 2018) who explain when measure the expression of CD8, Foxp3, CD19, and IL-10. Significant statistical increases and were observed that increase in the numbers of Foxp3+ and CD8+ inflammatory cells, as well as in

IL-10 expression, in the well differentiated tumors, compared to the poorly differentiated other tumors. Also these results are agreement with other previous studies(Jafari et al., 2019) who show that CD3+ T cells biomarkers were the predominant inflammatory cells in all groups, followed by CD19+ B cells.

Conclusions

- Different immune cell are involved in local response to humane hydatid cyst.

●CD19 suggest a more pronounced role of B-cell in liver of local IHC expression in that site.

●The suppressive effects of regulatory T cells and a considerable number of proliferating B cells may be the cause of the persistence of hydatid cysts in human cases for a long period.

Reference

1. BRUNETTI, E., KERN, P. & VUITTON, D. A. 2010. Expert consensus for the diagnosis and treatment of cystic and alveolar echinococcosis in humans. *Acta tropica*, 114, 1-16.
2. MORO, P. & SCHANTZ, P. M. 2009. Echinococcosis: a review. *International journal of Infectious diseases*, 13, 125-133.
3. BEKTAS, S., ERDOGAN, N. Y. & GUROL SAHIN, G. 2016. Clinicopathological Findings of Hydatid Cyst Disease: A Retrospective Analysis. *Ann Clin Pathol*, 4, 107
- CHAUTEMS, R., BUEHLER, L. H., GOLD, B., CHILCOTT, M. J., MOREL, P. & MENTHA, G. 2003. Long term results after complete or incomplete surgical resection of liver hydatid disease. *Swiss medical weekly*, 133, 258-62.
4. ZHENG, X., ZOU, Y. & YIN, C. 2015. Rare presentation of multi-organ abdominal echinococcosis: report of a case and review of literature. *International journal of clinical and experimental pathology*, 8, 11814.
5. NUNNARI, G., PINZONE, M. R., GRUTTADAURIA, S., CELESIA, B. M., MADEDDU, G., MALAGUARNERA, G., PAVONE, P., CAPPELLANI, A. & CACOPARDO, B. 2012. Hepatic echinococcosis: clinical and therapeutic aspects. *World journal of gastroenterology: WJG*, 18, 1448.
6. RUANGPRATHEEP, C., PADITAPORN, R., JINDATANMANUSAN, P. & ARNUTTI, P. 2017. The Optimal Immunohistochemical Staining Conditions for Engrailed 1 Protein. *Royal Thai Army Medical Journal*, 70, 193-202.
7. JAFARI, R., SANEI, B., BARADARAN, A., KOLAHDOUZAN, M., BAGHERPOUR, B. & DARANI, H. Y. 2019. Immunohistochemical observation of local inflammatory cell infiltration in the host-tissue reaction site of human hydatid cysts *Journal of helminthology*, 93, 277-285.
8. WHERRY, E. J., TEICHGRÄBER, V., BECKER, T. C., MASOPUST, D., KAECH, S. M., ANTIA, R., VON ANDRIAN, U. H. & AHMED, R. 2003. Lineage relationship and protective immunity of memory CD8 T cell subsets. *Nature immunology*, 4, 225.
9. WANG, K., WEI, G. & LIU, D. 2012. CD19: a biomarker for B cell development, lymphoma diagnosis and therapy. *Experimental hematology & oncology*, 1, 36.
10. GAVIN, M. A., TORGERSON, T. R., HOUSTON, E., DEROOS, P., HO, W. Y., STRAY-PEDERSEN, A., OCHELTREE, E. L., GREENBERG, P. D., OCHS, H. D. & RUDENSKY, A. Y. 2006.
11. Single-cell analysis of normal and FOXP3-mutant human T cells: FOXP3 expression without regulatory T cell development. *Proceedings of the National Academy of Sciences*, 103, 6659-6664.
12. SAKAMOTO, T. & CABRERA, P. A. 2003. Immunohistochemical observations on cellular response in unilocular hydatid lesions and lymph nodes of cattle. *Acta tropica*, 85, 271-279
13. CHEN , Z., ZHU, Y., DU, R., PANG, N., ZHANG, F., DONG, D., DING, J. & DING, Y. 2019. Role of Regulatory B Cells in the Progression of Cervical Cancer. *Mediators of Inflammation*, 2019.
14. CRAWFORD, A. R., LIN, X. Z. & CRAWFORD, J. M. 1998. The normal adult human liver biopsy: a quantitative reference standard. *Hepatology*, 28, 323-331.
15. BOSSOWSKI, A., URBAN, M. & STASIAK-BARMUTA, A. 2003. Analysis of Changes in the Percentage of B (CD19) and T (CD3) Lymphocytes, Subsets CD4, CD8 and their Memory (CD45RO), and Naive (CD45RA) T Cells in Children with Immune and Non-immune Thyroid Diseases. *Journal*

of Pediatric Endocrinology and Metabolism, 16, 63-70.

17. MONTALLI, V. A., PASSADOR-SANTOS, F., SOARES, A. B., MARTINEZ, E. F., RODRIGUES, D. B., ARAUJO, V. C. & NAPIMOGA, M. H. 2018. Correlation of

increased numbers of tumor-infiltrating T regulatory, CD19 and CD8 T cells in well differentiated oral squamous cell carcinoma. InterAmerican Journal of Medicine and Health, 1, e201801004-e201801004.