



Journal of Biological Sciences

ISSN 1727-3048

science
alert

ANSI*net*
an open access publisher
<http://ansinet.com>

RESEARCH ARTICLE

OPEN ACCESS

DOI: 10.3923/jbs.2015.177.186

Histological Sequences of Long Bone Development in the New Zealand White Rabbits

¹Yasser A. Ahmed, ²Eman A. Abdelrahim and ¹Fatma Khalil

¹Department of Histology, Faculty of Veterinary Medicine, South Valley University, Qena, 83523, Egypt

²Department of Histology, Faculty of Medicine, South Valley University, Qena, 83523, Egypt

ARTICLE INFO

Article History:

Received: August 15, 2015

Accepted: October 14, 2015

Corresponding Author:

Yasser A. Ahmed
Department of Histology,
Faculty of Veterinary Medicine,
South Valley University,
Qena, 83523, Egypt
Tel : +20965211223
Fax : +20965211223

ABSTRACT

Long bone development occurred through endochondral ossification. The current study investigated the main histological changes associated with the development of humerus from the New Zealand white rabbits. The upper limb or humerus during embryonic (12, 14, 15, 16, 18, 21, 24 and 27 days) and neonatal (3 and 7 days) development was processed for light microscopy. Three stages preceded endochondral ossification; limb bud (mesenchymal cells), cartilage primordia (mesenchymal condensation and differentiation into chondrocytes) and cartilage template (organization of chondrocytes into proliferative and hypertrophic zones) by 12, 14 and 15 days, respectively. At day 16, cartilage template elongated forming a cartilaginous diaphysis of the prospective humerus. At day 18, cartilaginous epiphyses were formed. Medullary cavity was established by day 21 with no signs of calcification in the bone collar. Primary ossification center appeared within the diaphysis at day 24 of embryonic development. Secondary ossification centers were seen within the epiphyses by day 3 of neonatal development. Two types of cartilage canals were investigated; short epiphyseal canals appeared from day 21 and long transphyseal canals appeared from day 27. At day 7 of neonatal development, the cartilage of the humerus was limited in two places; articular epiphyseal growth cartilage between articular surface and secondary ossification center, epiphyseal physeal growth cartilage between the secondary and primary ossification centers. The current study summarized the main histological stages of development of rabbit humerus. These results should be considered in molecular studies of endochondral bone formation.

Key words: Endochondral ossification, humerus, rabbit, histology

INTRODUCTION

Long bones, such as those of the limbs develop and grow through an organized and a highly dynamic process known as endochondral ossification. During embryonic development, the mesenchymal cells differentiate into chondrocytes, which laid down a cartilage template taking the shape and position of the prospective long bone (Mackie *et al.*, 2008). Two centers of ossification appear in the cartilage template. A Primary Ossification Center (POC) appears at the middle of the cartilage template and extends in both directions toward epiphysis (Tsumaki and Yoshikawa, 2005). A Secondary Ossification Center (SOC) appears at each end of the

prospective bone, leaving two pieces of cartilage; articular cartilage at the articular surface and growth plate between the POC and SOC. By maturity, the POC and SOC fuses together leaving only the permanent articular cartilage. The growth cartilage is formed of chondrocytes embedded in collagen (especially collagen type II) and proteoglycan-rich extracellular matrix (ECM) secreted and maintained by the chondrocytes themselves. Chondrocytes in the growth cartilage are organized into three dynamic zones; resting, proliferative and hypertrophic zones. Resting chondrocytes are randomly distributed throughout of the ECM and act as stem cells for the subsequent populations of cells. Proliferative chondrocytes are dividing flat cells which appear in parallel

columns. The proliferative cells undergo differentiation into two different populations of enlarged cells; light and dark hypertrophic chondrocytes (Ahmed *et al.*, 2007a, b; Chen *et al.*, 2010). The hypertrophic chondrocytes secrete specific collagen type X and alkaline phosphatase-rich matrix, which initiate calcification of the ECM. Light and dark cells die by non-apoptotic modes of physiological cell death leaving empty lacunae and the ECM undergo degradation by proteolytic enzymes such as metalloproteinases, which secreted by the hypertrophic chondrocytes (Ahmed *et al.*, 2007b). The degraded ECM is invaded by trout of bone marrow cells, blood vessels and bone cells (osteoblasts and osteoclast), depositing bone tissue on the cartilage remnant (Mackie *et al.*, 2008). Although the growth cartilage is avascular tissue, vascular channels are normally found to nourish the chondrocytes of growth cartilage of many avian and mammalian species during specific stages of development (Shingleton *et al.*, 1997; Blumer *et al.*, 2004). The current study aimed to monitor the main dramatic histological events of endochondral ossification of the long bone from the New Zealand white rabbits during a specific time period of embryonic and early postnatal development.

MATERIALS AND METHODS

Adult healthy female New Zealand white rabbits were raised in the animal farm related to Faculty of Agriculture, South Valley University, Qena, Egypt and used for the current study. The adult female rabbits were fertilized by two healthy male rabbits. Pregnancy was detected by abdominal palpation and confirmed by using ultrasonography. Pregnant rabbits were euthanatized at different stages of pregnancy (12, 14, 15, 16, 18, 21, 24 and 27 days of gestation) and their embryos were collected and rapidly fixed. Some pregnant rabbit were left to give birth after 28 days and their neonatal rabbits were euthanatized after 3 and 7 day of postnatal development. A total of fifty animals (40 embryos and 10 neonatals) were used for the current study. The developing upper limbs or the humerus (when applicable) were dissected and fixed in either 4% buffered paraformaldehyde for embedding in paraffin or in 2.5% glutaraldehyde in 4% buffered paraformaldehyde (Karnovsky's fluid), followed by 1.5% osmium tetroxide for embedding in Spurr's resin. Neonatal specimens were decalcified with 5% EDTA to assist sectioning. Serial paraffin and semithin sections were taken and stained with haematoxylin and eosin (H and E), Saffranin-O, PAS (Periodic Acid-Schiff), PAS-alcian blue, Crossman's trichrome, alizarin red and Von Kossa's stains (5 μm -thick-paraffin sections) and 1% toluidine blue (0.5 μm -thick-resin sections) and examined with light microscopy. Images presented were captured with a digital camera (LEICA, ICC50HD). All procedures were approved by the Ethics Committee of Scientific Research on experimental animals, Faculty of Veterinary Medicine, South Valley University, Qena, Egypt.

RESULTS

Light microscopic examination of paraffin and resin embedded sections from the upper limbs of the New Zealand white rabbits during prenatal and neonatal development revealed that projections from midway of the body known as upper limb buds were observed as early as day 12 of prenatal development (Fig. 1a). Limb bud consisted of uniformly distributed rounded undifferentiated mesenchymal cells encapsulated with an ectodermal layer of cuboidal epithelium (Fig. 1b). At day 14, mesenchymal cells showed concentric condensation at the site of the prospective humerus. Chondrogenesis began at this stage, when some mesenchymal cells differentiated into cartilage matrix secreting flattened chondrocytes. This piece of cartilage was termed as cartilage primordia, which appeared as a small rounded island of cartilage in a big sea of mesenchymal tissue (Fig. 1c). At day 15, the cartilage primordia elongated into a piece of cartilage template, which will form the diaphysis of the prospective humerus. The cartilage template is an oval structure of flattened chondrocytes embedded in a cartilage matrix (Fig. 1d). At day 16, the cartilage template elongated forming cartilaginous diaphysis of the prospective humerus (Fig. 1e) and the chondrocytes at the middle of the diaphysis begun hypertrophy (hypertrophic zone) and were surrounded by a connective tissue perichondrium. Chondrocytes on the periphery of the hypertrophic zone were flattened forming proliferative zones (Fig. 1f).

The cartilage template more elongated by day 18 taking the shape of the future humerus and consisted of a cartilaginous diaphysis and two epiphyses (Fig. 2a). The cartilage at the area of the epiphyses was termed as Epiphyseal Growth Cartilage (EGC) and that of diaphysis was termed as Physeal Growth Cartilage (PGC). Chondrocytes at the EGC was rounded to oval cells and randomly distributed throughout the ECM (Fig. 2b). Chondrocytes of the PGC were organized into a central hypertrophic zone of large rounded cells and the osteoid tissue begun deposits on the perichondrium forming periosteum (Fig. 2c). Some hypertrophic chondrocytes underwent physiological cell death as evidenced by the presence of cell remnants within empty lacunae. On both sides of hypertrophic zone, proliferative zones of flattened chondrocytes arranged in columns parallel to the long axis of the future humerus (Fig. 2d).

At the day 21, the medullary cavity was established at the middle of the prospective humerus (Fig. 3a) and zonation of PGC into proliferative and hypertrophic zones was more noticeable (Fig. 3b). Furthermore, more osteoid tissue was deposited within the periosteum and then the periosteal vascular invasion of the hypertrophic zone begun at this developmental stage. Bone collar (the osteoid tissue layer surrounding medullary cavity at the diaphysis) showed a negative reaction to Von Kossa indicating the absence of calcification at this developmental stage (Fig. 3c).

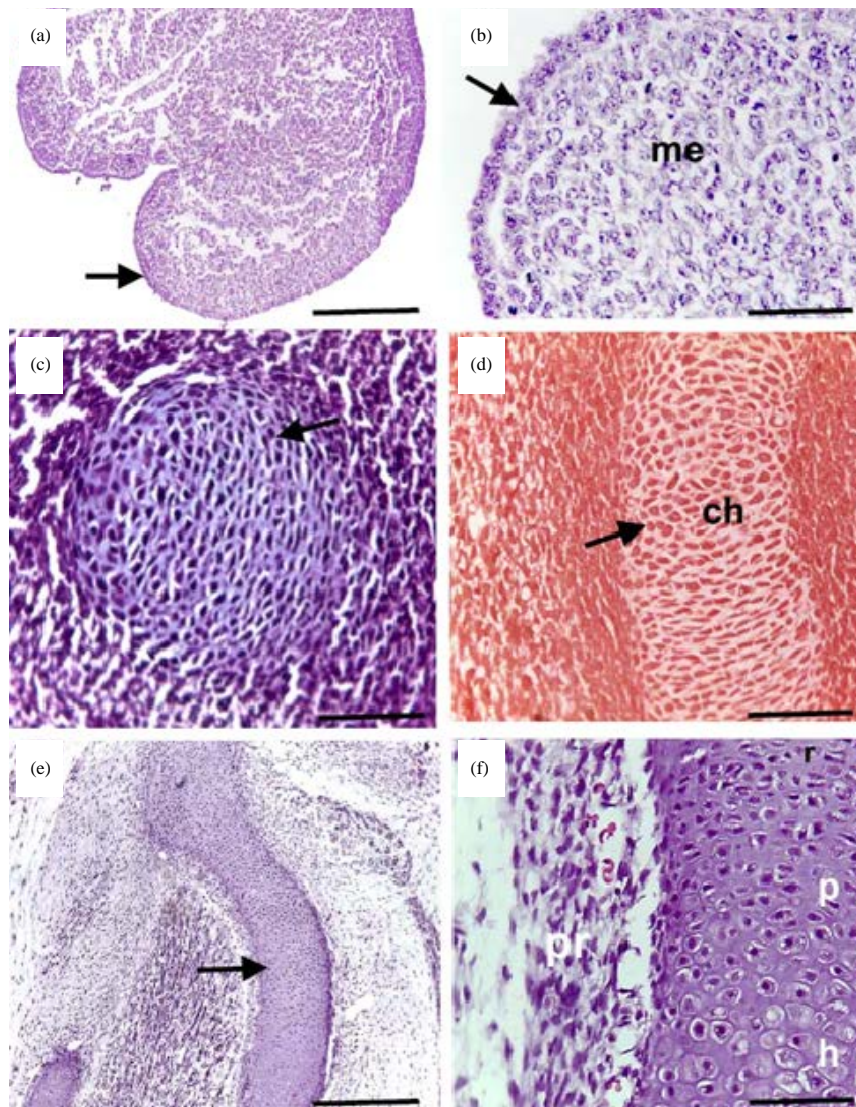


Fig. 1(a-f): Appearance of the limb bud, cartilage primordia and cartilage template. Light-micrographs of paraffin sections from the developing upper limb of the (a and b) 12, (c) 14 days, (d) 15 days and (e and f) 16 days old rabbit embryos stained with H and E (a, b, c, e, f) and (d) Safranin-O. Arrows indicate (a) Limb bud, (b) Ectodermal layer, (c) Cartilage primordia, (d) Cartilage template and (e) PGC. Note mesenchymal tissue (me) in b, chondrocytes (ch) in d and perichondrium (pr), resting chondrocytes (r), proliferating chondrocytes (p) and hypertrophic chondrocytes (h) in f. Bars = 1000 μ m in a-e and 100 μ m in f

At day 24, calcified medullary bone trabeculae were established as confirmed by Von Kossa and alizarin red staining reactions (Fig. 4a-d). Thus, the POC was seen for the first time at this developmental stage.

The humerus increased in length and width and became more developed by advancing in age. In addition to the well-developed POC, the SOC was seen in the EGC at day 3 of neonatal development (Fig. 5a). At this stage, the growth cartilage was limited into two places; the articular epiphyseal Growth Cartilage (AEGC) between the articular surface and

the SOC and Epiphyseal Physeal Growth Cartilage (EPGC) between the POC and SOC. The SOC consisted of bone trabeculae separated by medullary tissue (Fig. 5b). At day 7 of neonatal development, the SOC expanded (Fig. 5c and d). Chondrocytes surrounding the SOC underwent hypertrophy and osteoclasts were observed close to the opened lacunae of hypertrophic chondrocytes (Fig. 5d). The most dramatic histological changes associated with humerus development from embryonic and neonatal New Zealand rabbits were summarized in Table 1.

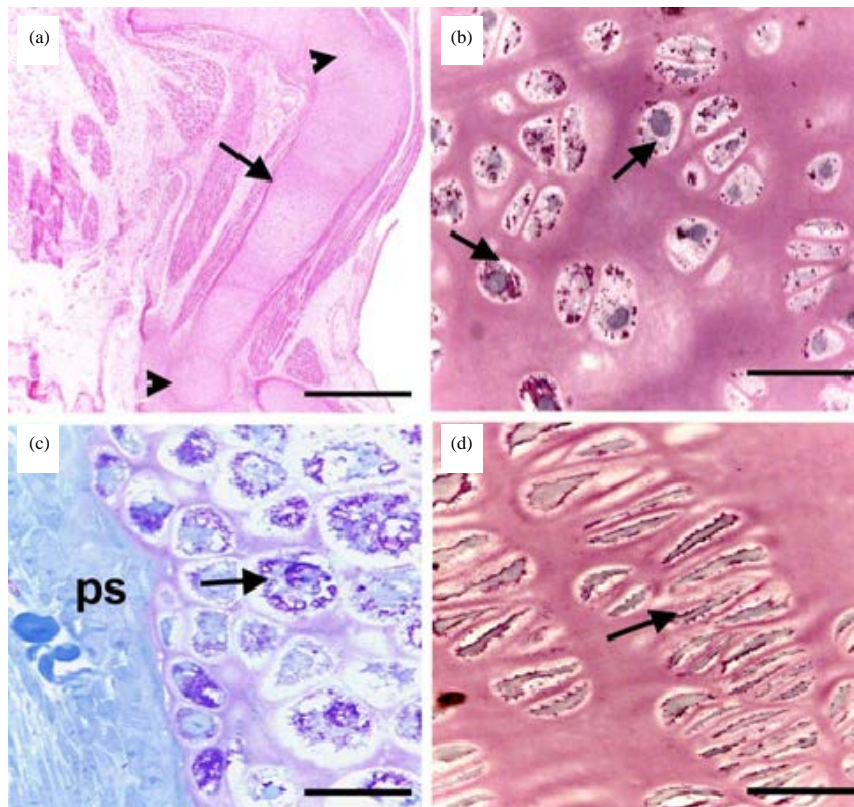


Fig. 2(a-d): Formation of the cartilaginous prospective humerus. Light micrographs of (a) Paraffin and (b-d) Semithin sections from the growth cartilage of 18 days old rabbit embryos stained with H and E and (b-d) toluidine blue. Arrowheads indicate the (a) EGC and PGC, (b) Resting chondrocytes of the EGC, (c) Hypertrophic and (d) Proliferative preoperative and zones of the PGC. Note periosteum (ps) in c. Bars = 1000 μ m in a and 40 μ m in b-d

Table 1: Summary of main histological events associated with development of the humerus from embryonic and neonatal New Zealand white rabbits

Age (days)	Main histological events
Prenatal developmental stages	
12	Formation of limb buds
14	Appearance of cartilage primordia
15	Formation of cartilage template
16	Formation of cartilaginous diaphysis of prospective humerus
18	Formation of cartilaginous epiphyses of prospective humerus
21	Formation of medullary cavity
	Formation of osteoid without calcification in bone collar
24	Appearance of short epiphyseal cartilage canals
	Mineralization of the osteoid tissue at the middle of the bone
27	Formation of POC and bone trabeculae
	Well organization of the chondrocyte zones within the PGC
	Appearance of long transphyseal cartilage canals
Neonatal developmental stages	
3	Formation of the SOC
	Separation of the growth cartilage into AEGC and PGC
7	Ossification proceeding and more chondrocyte organization into different zones

Development of cartilage canals within the humerus of New Zealand white rabbits:

Short cartilage canals were observed within the EGC of the prospective humerus for the first time at day 21 and termed as epiphyseal cartilage canals; ECC (Fig. 6a). A small number of ECC appeared to originate from the periarticular connective tissue and penetrated the EGC but never extended beyond the proliferative zone of the PGC (Fig. 6b). Later on, the ECC increased in number and depth and some of them penetrated into the SOC (Fig. 6c). In addition to the short ECC, another longer type of cartilage canals were seen for the first time by day 27, which extended deeper reaching the hypertrophic zone of the PGC and termed as transphyseal cartilage canals; TCC (Fig. 6d). The contents of the cartilage canals were different according to the stage of development. The early ECC contained only undifferentiated mesenchymal cells, a large amount of connective tissue, RBCs and blood vessels (Fig. 6e), while the both the ECC penetrating the SOC and the TCC contained also osteoblasts and osteoclasts (Fig. 6f). By day 7 of neonatal development, both types of cartilage canals were much well developed.

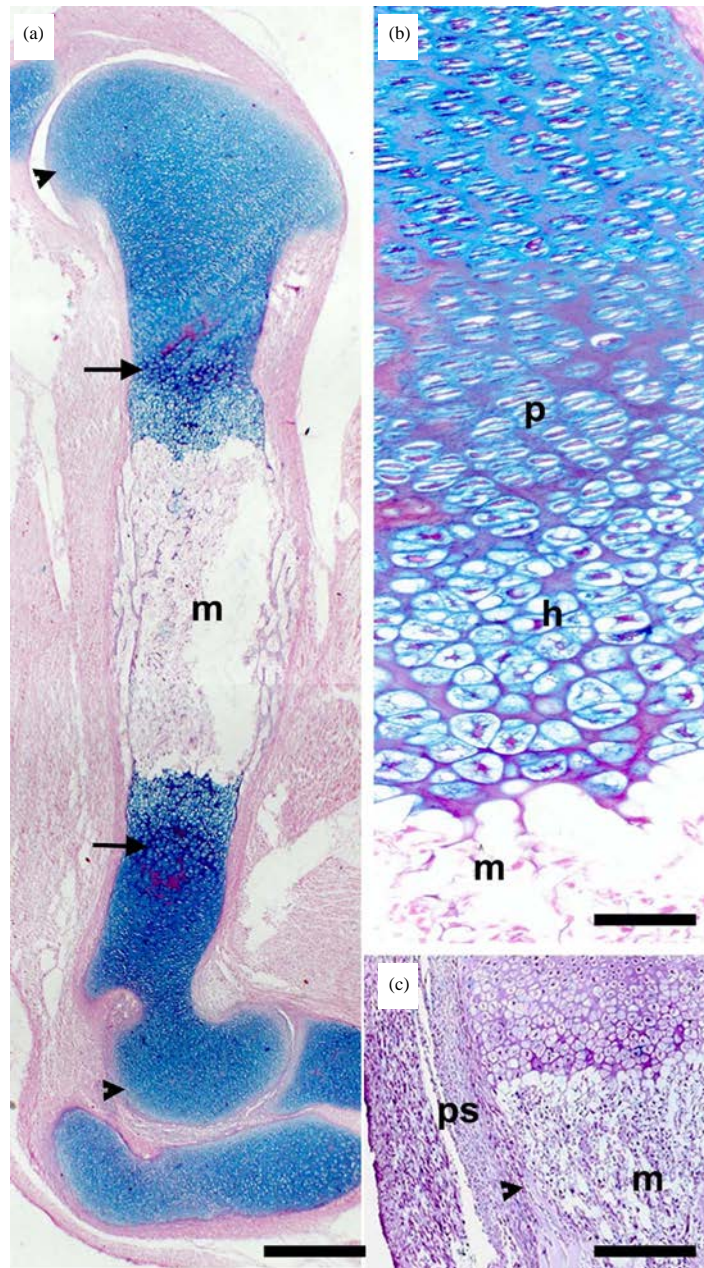


Fig. 3(a-c): Establishment of the medullary cavity. Light micrographs of paraffin sections from the prospective humerus of 21 days old rabbit embryos stained with (a and b) alcian blue-PAS and (c) Von Kossa. Arrowheads indicate (a) EGC and (c) Osteoid tissue of bone collar. Arrows indicate (a) PGC. Note medullary cavity (m) in A-C, proliferative (p) and hypertrophic (h) Zonation of the PGC in (b) and periosteum (ps) in (c). Bars = 1000 μ m in A and 400 μ m in b and c

DISCUSSION

Development of humerus from New Zealand white rabbits:

Although the enormous literature on endochondral ossification, there is a shortage in the studies concerned with timing the histological stages of long bone development

especially during embryonic development. To our best knowledge, there is only a study describing the histological development of long bone of rabbit (Rivas and Shapiro, 2002), however, it did not cover in details the histological sequences associated with long bone development as we have done in the present work. Thus, the current study was undertaken with the

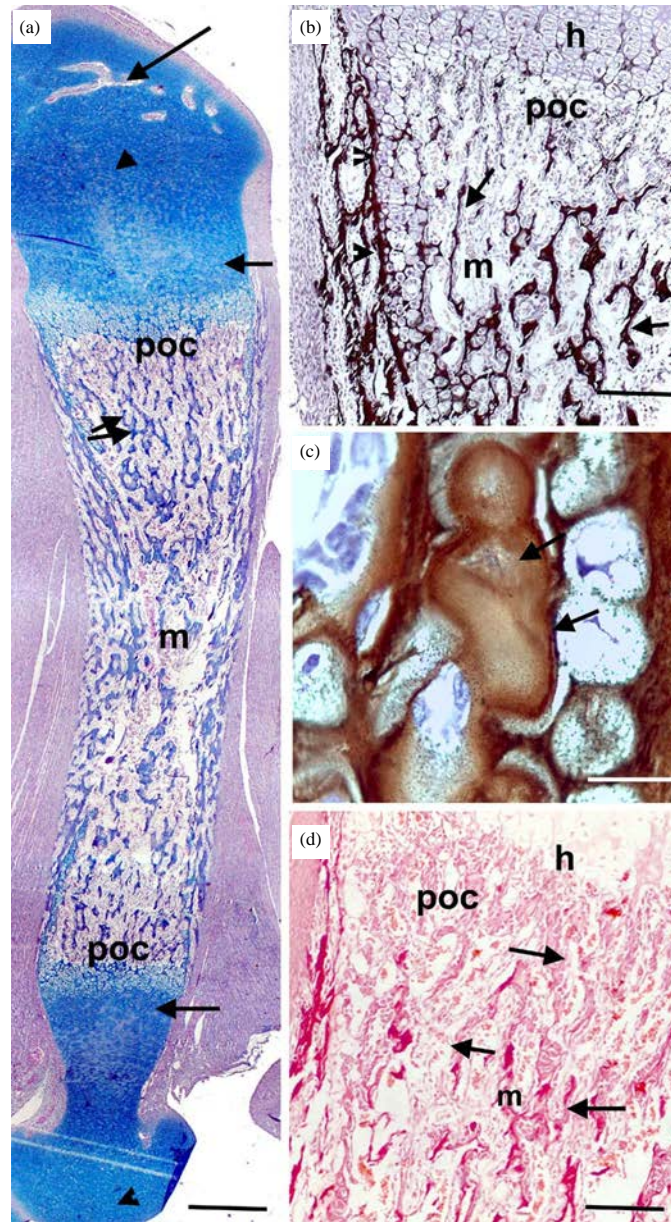


Fig. 4(a-d): Appearance of the primary ossification center. Light micrographs of paraffin sections from the humerus of 24 days old rabbit embryos stained with (a) Alcian blue-PAS (b and c) Von Kossa and (d) Alizarin red. Arrowheads indicate the (a) EGC and (b) Calcified bone collar. Arrows indicate the (a) PGC, (b and d) Calcified medullary bone trabeculae and calcified ECM of the hypertrophic zone and (a) double arrows indicate the increased medullary bone trabeculae (a). Note the medullary cavity (m) in A-D, hypertrophic zone (h) and the POC (poc) in b and d. Bars = 400 μ m in a, b, d and 100 μ m in c

aim of investigation of histological changes associated with humerus development during prenatal and neonatal life. To achieve this aim, specimens from the upper limb (or only humerus when applicable) from New Zealand white rabbits were processed for light microscopic examination. The current study revealed that the long bone development included three main stages preceded endochondral ossification

or bone formation. The manner of developmental sequences of New Zealand white rabbits reported in this study was similar to those in other mammals (Mackie *et al.*, 2008). Limb bud formation was observed at the day 12 of prenatal development. This result is in an agreement with another study carried out on rabbit embryos (Rivas and Shapiro, 2002). One of the most important signals initiating limb

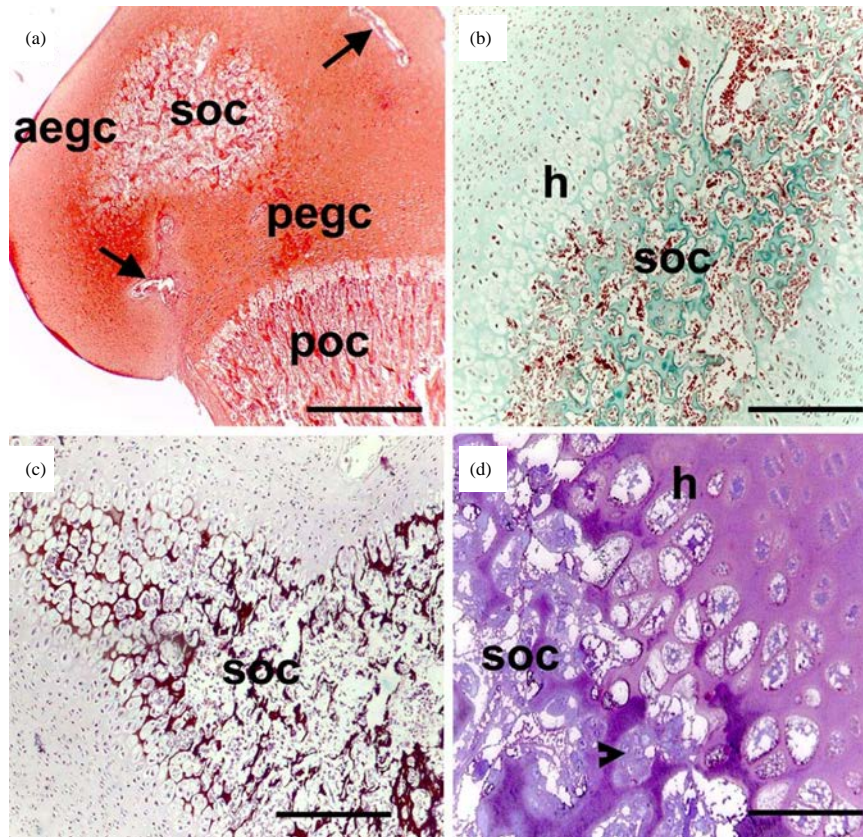


Fig. 5(a-d): Appearance of the secondary ossification center. Light micrographs of paraffin sections from the (a and b) Humerus of 3, (c and d) 7 days old rabbits stained with (a) Safranin-O, (b) Crossman's trichrome, (c) Von Kossa and (d) Toluidine blue. Arrowhead indicates (d) Osteoclast. Note the SOC (soc) in A-D, POC (poc), AEGC (aegc) and PGC (pegc) in a and hypertrophic chondrocytes (h) in b, d. Bars =1000 μ m (a-c) and 400 μ m (d)

bud formation is *Pitx1* and *Tbx4*, that expressed by limb mesenchymal cell (Duboc and Logan, 2011). Mesenchyme cells of the limb bud converted into chondrogenic cells resulted in the formation of cartilage primordia by day 14 of gestation which developed into cartilage template by day 15, when chondrogenic cells secreted glycosaminoglycan (GAG) rich cartilage matrix as confirmed by Safranin-O positive staining. This result is in an agreement with other studies in rabbit embryos which reported that formation of cartilage primordia begins at the 14th day and continues to the 15th day of gestation (Rivas and Shapiro, 2002). It is known that *Sox9* is essential for differentiation of mesenchymal cells into chondrogenic cells and secretion of ECM (Shimizu *et al.*, 2007). The cartilaginous diaphysis of the prospective humerus was noticed by day 15 and then by day 16 the chondrocytes were clearly organized into proliferative and hypertrophic zones within the diaphysis. At day 18 of gestation, cartilaginous diaphysis (PGC) elongated and cartilaginous epiphyses (EGC) were also formed, thus at this developmental stage the prospective humerus was entirely formed of cartilage. Activation of PTHrP receptor results in suppression of hypertrophy of chondrocytes and leads

to elongation of the cartilage template (Shimizu *et al.*, 2007; Kim *et al.*, 2008). Regulation of proliferation and hypertrophy of chondrocyte cycle is due to interactions between *Ihh*, PTHrP, *Runx2* and *Runx3* (Yoshida and Komori, 2005; Shimizu *et al.*, 2007). At day 21 of prenatal development, the medullary cavity was established and osteoid tissue was formed without signs of calcification. The PGC underwent endochondral ossification resulting in the formation of the POC and calcified medullary bone trabeculae by day 24 of embryonic development. Unlike our results, another study in embryonic rabbits reported that POC can be seen as early as day 18 of gestation (Rivas and Shapiro, 2002), however the authors have not confirmed their results with specific staining to detect calcification as we have done in the current study, making our result is more likely acceptable. The SOC was observed by day 3 and expanded by day 7. After formation of the SOC, the cartilage was only limited into two parts; the AEGC between articular surface and SOC and the EPGC or growth plate between SOC and POC. The AEGC is responsible for the expansion of epiphysis of long bone, while EPGC act for the elongation of long bone diaphysis (Mackie *et al.*, 2008).

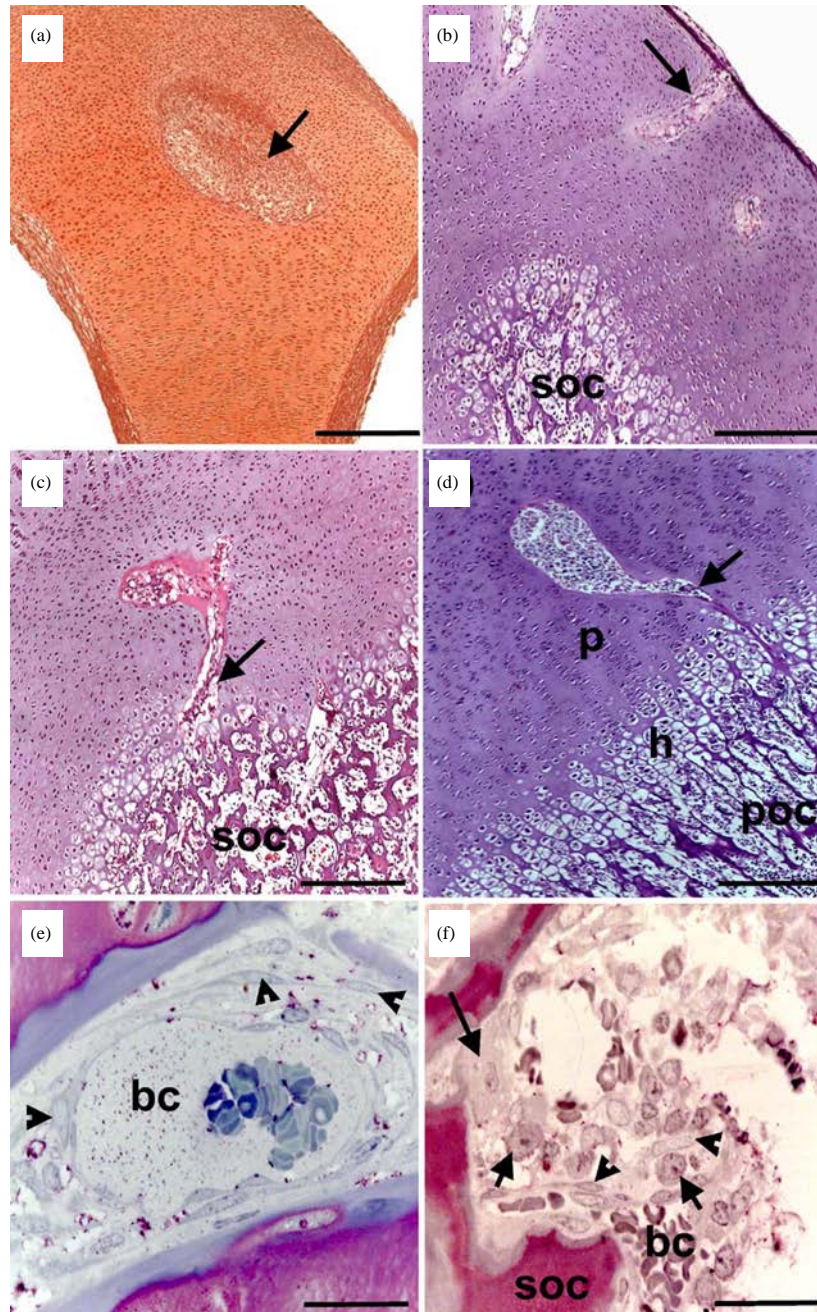


Fig. 6(a-f): Cartilage canals development. Light micrographs of (a-d) Paraffin, (e and f) Semithin sections from the growth cartilage of (a, e) 21 and (b) 24 days old rabbit embryos and (b) 3 and (c, d, f) 7 days old rabbits stained with (a) Safranin-O, (b and c) H and E, (d) PAS and (E-F) Toluidine blue in. Arrows indicate (a-d) Cartilage canals in and (f) Osteoclasts. Short arrows indicate (f) Osteoblasts. Arrowheads indicate (e and f) Mesenchymal cells. Note the SOC (soc) in B, C, F, the POC (poc) in d, proliferative (p) and hypertrophic chondrocytes (h) in d and blood capillary (b-c) in E, F. Bars = 400 μ m (a-d) and 40 μ m (e-f)

Development of cartilage canals within the humerus of New Zealand white rabbits: Although the cartilage of the mature rabbit known to be avascular tissue, the current study revealed the presence of vascular channels (cartilage canals)

within the growth cartilage of rabbits. Cartilage canals have been described in mammalian (Shingleton *et al.*, 1997; Rivas and Shapiro, 2002) and avian (Blumer *et al.*, 2004; Ahmed and Soliman, 2013) species and contain vascular

elements responsible for the maintenance of the growth cartilage. The time of appearance and disappearance of cartilage canals is different from species to another. In the current study, the first cartilage canals appeared by day 21 of gestation and continued till the last day of the study (7 days of neonatal development). In horses, they are common to be present by day 130 of the gestation period, (Shingleton *et al.*, 1997) and disappears in the postnatal animals. In Quail, they can be firstly observed by day 9 and are absent in growth cartilage from 6 weeks old birds. In the current study, it was shown that the cartilage canals appeared as invaginations from the perichondrium and periarticular connective tissue penetrating into the non-calcified cartilage matrix. Furthermore, two types of cartilage canals were described. The early short ECC, which never exceeded the proliferating zone but may penetrate into the SOC in older ages and the longer TCC, which usually extended behind the proliferating zone reaching the POC. Similarly, in the developing cartilage of chicken, it was reported, also, two types of cartilage canals; "Shell" and "Communicating" canals. "Shell canals" are usually restricted to the superficial layers of the growth cartilage, while the communicating canals pass downward into the deeper layers (Blumer *et al.*, 2004). Contents of the cartilage canals varied during different developmental stages. The contents of short ECC were undifferentiated mesenchymal cells, loose connective tissue and blood vessels, while long TCC and ECC penetrating the SOC contained also osteoblasts and osteoclasts. It is likely that the early ECC may play a role in the nutrition of the developing cartilage, while ECC penetrating the SOC and the TCC are important for ossification. In another study, the cartilage canals were shown to contain mesenchymal cells, osteogenic cells and blood vessels. These contents suggested to provide both the vasculature and nutrition to the growing chondrocytes as well as mesenchymal cells, precursors of osteoblasts, that may be needed to the formation of the SOC and osteoclasts need for degradation of cartilage remnants, which present in the margins and tip of cartilage canals (Blumer *et al.*, 2004; Blumer *et al.*, 2005; Blumer *et al.*, 2006; Blumer *et al.*, 2007; Blumer *et al.*, 2008). In addition, it was presented that some of the mesenchymal cells differentiated into osteoblasts that participate in the formation of medullary bone during endochondral ossification, while other mesenchymal cells differentiated into chondrocytes (Ytrehus *et al.*, 2004).

The current study described the main histological events associated with the development of the humerus of New Zealand white rabbits between day 12 of prenatal and day 7 of neonatal development. The results presented in this study should be considered in future molecular studies of endochondral bone formation.

ACKNOWLEDGMENT

The authors thank Dr. Soha Soliman, the lecturer of Histology, Faculty of Veterinary Medicine, South Valley University, Qena, Egypt for assisting in sample collection.

REFERENCES

- Ahmed, Y.A. and S.A. Soliman, 2013. Long bone development in the Japanese Quail (*Coturnix coturnix Japonica*) embryos. Pak. J. Biol. Sci., 16: 911-919.
- Ahmed, Y.A., L. Tatarczuch, C.N. Pagel, H.M. Davies, M. Mirams and E.J. Mackie, 2007a. Hypertrophy and physiological death of equine chondrocytes *in vitro*. Equine. Vet. J., 39: 546-552.
- Ahmed, Y.A., L. Tatarczuch, C.N. Pagel, H.M. Davies, M. Mirams and E.J. Mackie, 2007b. Physiological death of hypertrophic chondrocytes. Osteoarthritis Cart., 15: 575-586.
- Blumer, M.J.F., H. Fritsch, K. Pfaller and E. Brenner, 2004. Cartilage canals in the chicken embryo: Ultrastructure and function. Anat. Embryol., 207: 453-462.
- Blumer, M.J.F., S. Longato, E. Richter, M.T. Perez, K.Z. Konakci and H. Fritsch, 2005. The role of cartilage canals in endochondral and perichondral bone formation: Are there similarities between these two processes? J. Anat., 206: 359-372.
- Blumer, M.J.F., C. Schwarzer, M.T. Perez, K.Z. Konakci and H. Fritsch, 2006. Identification and location of bone-forming cells within cartilage canals on their course into the secondary ossification center. J. Anat., 208: 695-707.
- Blumer, M.J.F., S. Longato, C. Schwarzer and H. Fritsch, 2007. Bone development in the femoral epiphysis of mice: The role of cartilage canals and the fate of resting chondrocytes. Dev. Dynamics, 236: 2077-2088.
- Blumer, M.J.F., S. Longato and H. Fritsch, 2008. Structure, formation and role of cartilage canals in the developing bone. Ann. Anatomy-Anatomischer Anzeiger, 190: 305-315.
- Chen, K.S., L. Tatarczuch, M. Mirams, Y.A. Ahmed, N.C. Pagel and E.J. Mackie, 2010. Periostin expression distinguishes between light and dark hypertrophic chondrocytes. Int. J. Biochem. Cell. Biol., 42: 880-889.
- Duboc, V. and M.P.O. Logan, 2011. Pitx1 is necessary for normal initiation of hindlimb outgrowth through regulation of Tbx4 expression and shapes hindlimb morphologies via targeted growth control. Development, 138: 5301-5309.
- Kim, Y.J., H.J. Kim and G.I. Im, 2008. PTHrP promotes chondrogenesis and suppresses hypertrophy from both bone marrow-derived and adipose tissue-derived MSCs. Biochem. Biophys. Res. Commun., 373: 104-108.
- Mackie, E.J., Y.A. Ahmed, L. Tatarczuch, K.S. Chen and M. Mirams, 2008. Endochondral ossification: How cartilage is converted into bone in the developing skeleton. Int. J. Biochem. Cell. Biol., 40: 46-62.
- Rivas, R. and F. Shapiro, 2002. Structural stages in the development of the long bones and epiphyses: A study in the New Zealand white rabbit. J. Bone Joint Surg. Am., 84-A: 85-100.

- Shimizu, H., S. Yokoyama and H. Asahara, 2007. Growth and differentiation of the developing limb bud from the perspective of chondrogenesis. *Dev. Growth Differentiation*, 49: 449-454.
- Shingleton, W.D., E.J. Mackie, T.E. Cawston and L.B. Jeffcott, 1997. Cartilage canals in equine articular/epiphyseal growth cartilage and a possible association with dyschondroplasia. *Equine Vet. J.*, 29: 360-364.
- Tsumaki, N. and H. Yoshikawa, 2005. The role of bone morphogenetic proteins in endochondral bone formation. *Cytokine Growth Factor Revi.*, 16: 279-285.
- Yoshida, C.A. and T. Komori, 2005. Role of Runx proteins in chondrogenesis. *Critical Rev. Eukaryotic Gene Exp.*, 15: 243-254.
- Ytrehus, B., C.S. Carlson, N. Lundeheim, L. Mathisen, F.P. Reinholt, J. Teige and S. Ekman, 2004. Vascularisation and osteochondrosis of the epiphyseal growth cartilage of the distal femur in pigs-development with age, growth rate, weight and joint shape. *Bone*, 34: 454-465.