

See discussions, stats, and author profiles for this publication at: <https://www.researchgate.net/publication/282272427>

# Teratogenic effects of hexachlorobenzene on the pregnant rats and their fetuses during gestation and lactation

Article in *Research Journal of Pharmaceutical, Biological and Chemical Sciences* · January 2015

CITATIONS

0

READS

27

4 authors, including:



[Abd el wahab El Ghareeb](#)

12 PUBLICATIONS 49 CITATIONS

[SEE PROFILE](#)



[Hamida Hamdi](#)

Cairo University

20 PUBLICATIONS 26 CITATIONS

[SEE PROFILE](#)

Some of the authors of this publication are also working on these related projects:



teratogenesis [View project](#)

# Research Journal of Pharmaceutical, Biological and Chemical Sciences

## Teratogenic Effects of Hexachlorobenzene on the Pregnant Rats and Their Fetuses during Gestation and Lactation.

Abd El Wahab El Ghareeb<sup>1\*</sup>, Hamida Hamdi<sup>1,2</sup>, Ahmed Ragab<sup>3</sup>, and Malak Mamdouh<sup>4</sup>.

<sup>1</sup>Zoology Department, Faculty of Science, Cairo University, Egypt.

<sup>2</sup>Biology Department, Faculty of Science, Taif University, Saudi Arabia.

<sup>3</sup>Zoology Department, Faculty of Science, Beni Suef University, Egypt.

<sup>4</sup>Zoology Department, Faculty of Science, Benha University, Egypt.

### ABSTRACT

Hexachlorobenzene (HCB) is one of the highly toxic and persistent compounds that are released unintentionally through various man-made chemicals. HCB had other applications, it was involved in several industrial processes: as a fluxing agent in aluminum smelting, as a regulator of porosity in the manufacture of graphite electrodes, and as a peptizing agent of rubber. The aim of this study was to evaluate the teratogenic effects of HCB on pregnant rats and their fetuses. Pregnant albino rats (*Rattus norvegicus*) were administered day after day an oral dose of 100mg/Kg from the 5th day of gestation till the end of lactation. The animals were sacrificed at the end of gestation and during lactation. Fetuses were removed from the uterus and evaluated for mortality rate, growth parameters, morphological and skeletal malformation as well as histological study of brain, liver and kidney. Results showed decreased weight gain of pregnant rats treated with HCB (100 mg/kg) during gestation and lactation. Fetal growth retardation during gestational and lactational period was dose and time dependent. Hematomas, anomalies of limbs (paralysis, oligodactyly), and exencephaly were noticed morphologically in the fetuses of the treated groups. Fetal skeletal abnormalities were most obvious with 100 mg/kg of HCB from the 5th to the 19th day of gestation. These abnormalities included defective ossification of central and peripheral skeletons, shortness of the terminal ribs, agenesis and wavy ribs. Histopathological studies of pregnant rats and their fetuses during gestation and lactation revealed congestion and dilatation of the central vein and fatty degeneration of the hepatocytes. Hydropic degeneration, inter-tubular hemorrhage, swelling of glomeruli and cloudy swelling of convoluted tubules were observed in kidney of treated groups while mild degenerative changes were observed in the brain following HCB administration. HCB pretreatment was able to increase the level of lipid peroxidation significantly. The correlation noted between GSH levels and HCB effects is significant. Our findings suggest the need for great caution to handle HCB especially during pregnancy and lactation.

**Keywords:** HCB, Teratogenicity, Gestation, Lactation

*\*Corresponding author*

## INTRODUCTION

Teratology, the study of abnormal prenatal development and congenital malformations induced by exogenous chemical or physical agents, continues to be a burgeoning area of medical research in the quest for the eradication of preventable birth defects. Identification of agents with teratogenic potential from the plethora of drugs and chemicals that human beings come into contact with in their everyday environment is crucial.

For decades it was believed that the placenta served as a barrier that protected the fetus from the adverse effects of drugs but further studies revealed that it is not completely protective.

Organochlorine pesticides are a group of chemicals made for the purpose of killing or otherwise deterring "pest" species. The lipophilic nature, hydrophobicity and low chemical and biological degradation rates of organochlorine pesticides have led to their accumulation in biological tissues and subsequent magnification of concentrations in organisms progressing up the food chain ([Swackhamer and Hites, 1988](#); [Vassilopoulou and Georgakopoulous-Gregoriades, 1993](#)).

Pesticides are applied in large quantities in agricultural, community and household settings. Some pesticides approved for agricultural use are also used to treat human ailments such as head lice or scabies. Pesticides can be ingested, inhaled, or dermally absorbed through contact with treated surfaces. The pathways of pesticide exposure include food, water, air, dust, and soil.

Organochlorine compounds, including pesticides, have been found to alter levels of maternal thyroid hormones during pregnancy. Women with HCB concentrations that ranged from 7.5-841.0 ppb (ng/mL) had altered thyroid hormone levels ([Chevieret et al., 2008](#)).

Neurodegenerative diseases such as Parkinson's disease and Alzheimer's disease are more common in people with general pesticide exposures, including organochlorine pesticide exposure ([Kamel and Hoppin, 2004](#)).

Hexachlorobenzene is a chlorinated aromatic hydrocarbon that exists as a white needle-like crystalline at room temperature (HSDB, 2010). It is practically insoluble in water, sparingly soluble in cold alcohol and carbon tetrachloride, and soluble in benzene, chloroform, ether, and carbon disulfide. It is stable under normal temperatures and pressures (Akron, 2010). It is combustible but it does not ignite readily. When HCB decomposes, it emits highly toxic fumes of hydrochloric acid, other chlorinated compounds, carbon monoxide, and carbon dioxide.

HCB is quite volatile, lipophilic and very resistant to breakdown in the environment. As a result, it can be transported over long distances and is bioaccumulated in fatty tissues (EFSA, 2006).

In the past, HCB had many uses in industry and agriculture. The major agricultural application was as a seed dressing for crops such as wheat, barley, oats and rye to prevent growth of fungi. HCB was used in conventional cereal crops until the 1980's as a seed treatment against fungal infections ([Wagner et al., 2013](#)).

The use of HCB in such applications was discontinued in many countries in the 1970s owing to concerns about adverse effects on the environment and human health. Hexachlorobenzene may continue to be used for this purpose in some countries; for example, HCB was still used in 1986 as a fungicide, seed-dressing and scabicide in sheep in Tunisia ([Government of Canada, 1993](#); [WHO, 1997](#)).

Hexachlorobenzene had other applications. It was involved in several industrial processes: as fluxing agent in aluminum smelting, as a regulator of porosity in the manufacture of graphite electrodes, as peptizing agent of rubber. It was used for manufacture of military pyrotechnics and went into the composition of wood preservatives. HCB was a synthetic intermediate in the production of certain rubber and chlorinated aromatic compounds (INERIS, 2005). [Xiaochu Gan et al., \(2012\)](#) presented a new and easy method to synthesize graphene at a low temperature of 360 °C. HCB was used as a solid carbon source.

Hexachlorobenzene in sediments can enter the food chain by uptake by small organisms in direct contact with sediment. HCB is primarily found in fatty food. Fish and fish oil are known to contain high level of

HCB. It is distributed into all organs. The time required to reach equilibrium depends markedly on the administration route; after oral administration of HCB in oil, it is 2 to 5 days. The highest concentrations are found in adipose tissue (BUA, 1994). In the rat, high concentrations are also found in endocrine tissues such as the thyroid gland, adrenal glands and ovaries (Foster et al., 1993).

Ingestion of HCB is the major route for human exposure (Chris, 1994), inhalation or dermal is not a major route of contamination but animal studies have demonstrated cutaneous absorption in rats.

The excretion of HCB is slow and occurs mainly through the faeces with relatively little being excreted in the urine. In rats, about 7% of a single dose is eliminated in urine and 27% in faeces as metabolites over a 4 week period (Courtney, 1979). A number of studies demonstrated that a significant portion of the maternal HCB body burden may be eliminated through breast milk (Bailey et al., 1980; Bleavins et al., 1982, 1984a).

The International Agency for Research on Cancer (IARC) has classified HCB under group 2B. Evidence for carcinogenicity to humans is inadequate but there is sufficient evidence for carcinogenicity in animals (IARC, 1979 & 1987).

Studies of reproductive toxicity have indicated that the ovary and testis are target sites for HCB toxicity. Female animals dosed with a high dose of HCB develop altered ovarian steroid levels, as well as alterations in the pituitary hormones, FSH and prolactin (Alvarez et al., 2000). In addition to altering function, HCB induced structural changes have been observed in the ovary (Alvarez et al., 2000). Male reproduction is also altered by repeated exposure to HCB, with histological changes in the testes and reduced serum testosterone levels reported (Elissalde and Clarke., 1979).

Oxidative stress can be defined most simply as the imbalance between the production of free radicals capable of causing peroxidation of the lipid layer of cells and the body's antioxidant defense (Mohammed et al., 2004). It not only causes hazardous events such as lipid peroxidation and oxidative DNA damage, but also physiologic adaptation phenomena and regulation of intracellular signal transduction.

Higher levels of some of the OCP residues may be associated with PTD and increased oxidative stress. However, a small sample size in the study limits the sensitivity and statistical power of our data and we recommend that the role of OCPs in PTD cases and increased oxidative stress should be interpreted with caution. Reactive oxygen species (ROS) have been proposed to play an important role in the pathogenesis of the porphyria caused by polyhalogenated aromatic hydrocarbons, such as HCB (Ferioliet al., 1984; Almeida et al., 1997; Billi de Catabbiet al., 1997). Waterborne HCB at environmental realistic concentrations could result in oxidative stress in common carp. Compared to liver, brain was more sensitive to the oxidative damage and supposed to be one of the most important target organs of HCB intoxication in fish.

The present study mainly concentrates on the teratogenic effects of HCB on pregnant rats and their fetuses during gestation and lactation.

## MATERIALS AND METHODS

### Experimental animals

The present experimental study is thus carried out on the white albino rat (*Rattus norvegicus*). The standard guidelines of the Institutional Animal Care and Use Committee (IACUC) were used in handling animals.

Females of 11-13 weeks old were selected for the present study and vaginal smears prepared every morning and examined under the light microscope according to the method of Snell, (1956) for 5 days to select those in the pro-estrus. Two females with regular estrus cycle were selected in the pro-estrus stage and caged together with one male over night under controlled environmental conditions of temperature, humidity and light. The first day of gestation was determined by the presence of sperms in the vaginal smear (McClain and Becker, 1975).

A daily record of the weight of the pregnant females was made throughout the whole gestational period. The percentages of abortion were calculated in each group; abortion was determined by the presence of blood drops and sudden drop in the weight of the pregnant female.

#### **Experimental strategy**

Hexachlorobenzene (HCB; purity > 99%) was purchased from BDH Chemicals-England. In the present investigation, a range of doses used to determine the sub lethal dose which induces teratogenic effect.

#### **Experimental design**

**Route of administration:** Oral.

**Time of administration:** Scheduled from the 5<sup>th</sup> day of gestation, day after day during both gestation and lactation.

#### **4-Experimental groups**

**Group (A):** Control group received pure olive oil from 5<sup>th</sup> day to 21<sup>st</sup> day of lactation.

**Group (B):** Treated group received 100mg/ Kg of HCB from 5<sup>th</sup> day of gestation to 21<sup>st</sup> day of lactation.

#### **Developmental observations**

On the 20<sup>th</sup> day of gestation, all pregnant rats of groups (A-B) were sacrificed and total implantation sites, fetal mortality rate (resorped or still birth) and living fetuses were recorded. On the 7<sup>th</sup>, 14<sup>th</sup> and 21<sup>st</sup> day of lactation respectively the neonates of groups (A-B) were sacrificed. Fetal body weight, body length, tail length and external malformation were recorded.

#### **Examination of the external features:**

The fetuses were examined for the occurrence of any malformation. In the head, neck areas as well as the limbs.

#### **Sample preparation**

On the 20<sup>th</sup> day of gestation, all pregnant rats of groups (A-B) were sacrificed by decapitation.

On the 7<sup>th</sup>, 14<sup>th</sup> and 21<sup>st</sup> day of lactation respectively the neonates of groups (A-B) were sacrificed by decapitation.

The brain was extracted and parts of the liver, kidney, and brain tissues of pregnant rats and fetuses of different groups were fixed and prepared for general histopathological studies.

#### **Skeletal examination**

Fetuses were preserved in 95% ethyl alcohol and were stained with double staining of fetal skeletons for cartilage (blue) and bone (red) according to the method described by Peters, (1977).

#### **Oxidative stress investigation**

0.2gm of organ tissue was homogenized in 2ml of phosphate buffer. The homogenate was centrifuged and the clear supernatant was kept in deep freezer at -40°C for oxidative stress studies.

#### **Determination of Glutathione reduced content**

Glutathione content was determined according to the procedure of (Beutler et al., 1963).

### Determination of lipid peroxidation

Lipid peroxidation was determined according to the procedure of (Satoh, 1978; Ohkawa, et al., 1979).

### Statistical analysis

All the values were presented as means ( $\mu$ )  $\pm$  standard errors of the means (S.E.M.) Comparison between more than two different groups was carried out using the one-way analysis of variance (ANOVA) followed by Turkey-Kramer's multiple comparison test (Armitage and Berry, 1987), where  $P < 0.05$  was considered significant. GraphPad Software InStat (version 2) was used to carry out the statistical tests.

## RESULTS

### Effects of Hexachlorobenzene on pregnant albino rats and their fetuses during gestation

#### Pregnant albino rats

#### Change in body weight

The maternal body weight was followed all over the period of gestation for the control and the experimental group. The average maternal body weight and the average increase in weight (table 1).

**Table1: Changes in weight gain of pregnant rats during gestational period.**

Groups of mothers	Average Wt. of mothers at the 5 <sup>th</sup> day of gestation	Average Wt. of mothers at the 20 <sup>th</sup> day of gestation	Average increase in weight	Percentage of increase
Group A control)(	233.17	273.29	40.12 <sup>a</sup> $\pm$ 4.51	17.206%
Group B treated)(	210.75	239.510	28.76 <sup>b</sup> $\pm$ 3.17	13.64%

Sample size (n)= 20

Data are represented as mean  $\pm$  standard error.

Means with the same letter in the same parameter are not significantly different.

F-probability expresses the effect between groups, where  $P < 0.0001$  is very highly significant.

Effect of HCB on uteri and the average wt. of placenta was also detected and recorded in (table 2 & fig.1).

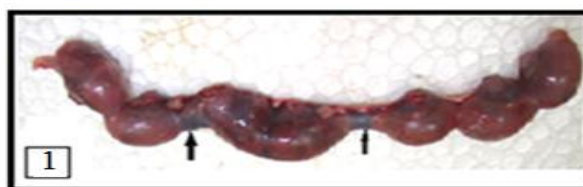**Table2: Effect of HCB on uteri and average weights of placenta of pregnant rats on the 20<sup>th</sup> day of gestation.**

Groups of mothers	Total no. of uteri	No. of uteri without resorption	No. of uteri with partial resorption	Average weight of placenta
Group A control)(	20	-	-	0.5140 <sup>a</sup> $\pm$ 0.00135
Group B treated)(	20	11	9	0.4769 <sup>b</sup> $\pm$ 0.00349

Data are represented as mean  $\pm$  standard error.

Means with the same letter in the same parameter are not significantly different.

F-probability expresses the effect between groups, where  $P < 0.0001$  is very highly significant.



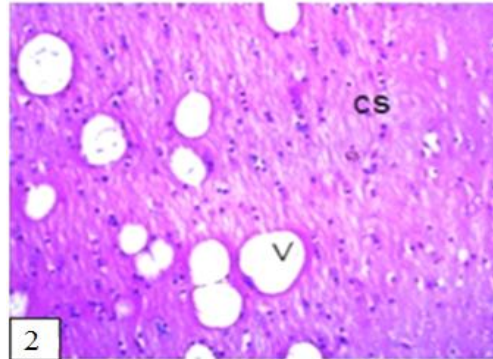
**Fig. 1: A photograph of uterus of pregnant female albino rat on the 20<sup>th</sup> day of gestation treated with (100mg/Kg) HCB from (5<sup>th</sup> to 19<sup>th</sup> day of gestation) shows partial resorption (arrow) in two horns and asymmetrical distribution of fetuses.**

#### Histological studies of pregnant albino rats

Examination of serial transverse sections of the brain, liver, kidney and placenta of albino pregnant rat treated with HCB on the 20th day of gestation showed some histological changes as decrease in the number and size of trophoblastic giant cells, Cystic degeneration of glycogen cells, degeneration in basal

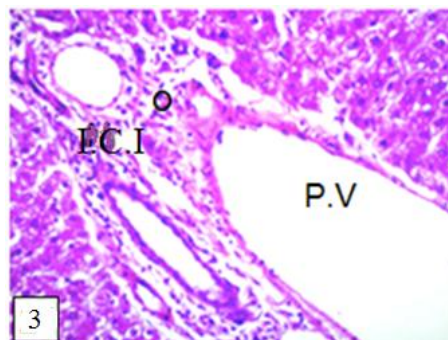


layer and massive hyperemia in the labyrinth interhemal membrane of the placenta. The cerebrum of pregnant rats treated with HCB on the 20th day of gestation showed some histological changes in the brain, such as focal encephalomalacia and focal plaques formation as well as vacuolization in the matrix of striatum in the cerebrum (fig. 2). The cerebellum of treated pregnant rats showed vacuolization in the medulla of white matter with degeneration in purkinje cell layer.

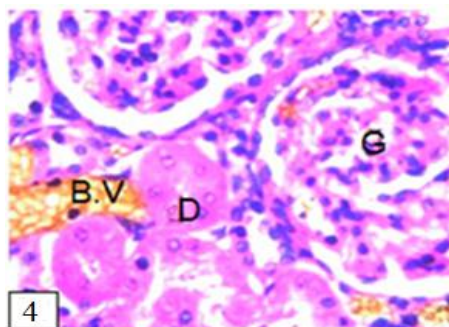


**Fig. 2: A photomicrograph of a section of brain of pregnant albino rats treated with (100mg/ Kg) HCB from (5<sup>th</sup> to 19<sup>th</sup> day of gestation) shows vacuolization (v) in the matrix of striatum in the cerebrum (cs). (H&E)(40X)**

The liver of treated pregnant rats showed fatty change in the hepatocytes as well as inflammatory cells infiltration and oedema that were detected in the portal area associated with severe dilatation in the portal vein (fig. 3).The kidney of treated mothers revealed some histopathological changes such as swelling and proliferation in lining endothelium of the glomerular tufts with degeneration of lining epithelium of the tubules with congestion in blood vessels (fig. 4). Focal hemorrhages at the. corticomedullary portion.



**Fig. 3: A photomicrograph of a section of liver of pregnant albino rats treated with (100mg/Kg) HCB from (5<sup>th</sup> to 19<sup>th</sup> day of gestation) shows oedema (O) with inflammatory cells infiltration (I.C.I) in portal area with severe dilatation in portal vein (P.V). (H&E) (40X)**



**Fig. 4: A photomicrograph of a section of kidney of pregnant albino rats treated with (100mg/Kg) HCB from (5<sup>th</sup> to 19<sup>th</sup> day of gestation) shows swelling and proliferation in lining endothelium of the glomerular tufts (G) with swelling and degeneration of lining epithelium of the tubules (D) with congestion in blood vessels (B.V). (H&E) (80x)**

**Effects of HCB on albino rat fetuses during gestation**

**Fetal mortality**

Total mortality rate included resorbed fetuses and stillbirths (dead fetuses at birth) and was recorded for both control and experimental groups (table 3).

Total mortality rate of fetuses maternally treated with 100mg/Kg HCB was 13.07% compared to the control group (table 3).

**Table 3: Effect of HCB on fetal mortality on 20<sup>th</sup> day of gestation.**

Groups	Total no. of sacrifice-ed rats	No. of implanta-tion sites	No. of live fetuses		No. of resorbed fetuses		No. of dead fetuses		Total mortality rate	
			No.	%	No.	%	No.	%	No.	%
Group A (Control)	20	168	168	100%	-	-	-	-	-	-
Group B (Treated)	20	153	147	96.07%	15	9.8%	5	3.26%	20	13.07%

The data are represented as percentage (%)

**Growth retardation:**

The morphological examination of fetuses showed that HCB caused growth retardation represented by decrease in fetal body weight, body length and tail length (table 4).

**Table 4: The body weight, body length and tail length of fetuses on the 20<sup>th</sup> day of gestation.**

Groups of fetuses during gestation	Average body wt. of fetuses	Average body length of fetuses	Average body tail length of fetuses
Group A (control)	3.599 <sup>a</sup> ± 0.099	5.051 <sup>a</sup> ± 0.254	1.532 <sup>a</sup> ± 0.066
Group B (Treated)	2.103 <sup>b</sup> ± 0.708	3.259 <sup>b</sup> ± 0.458	1.111 <sup>b</sup> ± 0.188

Data are represented as mean ± standard error.

Means with the same letter in the same parameter are not significantly different.

F-probability expresses the effect between groups, where P<0.0001 is very highly significant.

**Morphological malformations**

The malformations found in fetuses from treated group were hematoma, anomalies of limbs, dorsal and head. Asoligodactyly and contraction of fore limb (table 5&6- figs. 5,6&7).

**Table 5: Effect of HCB on the percentage of hematoma in fetuses on the 20<sup>th</sup> day of gestation.**

Groups	No. of examined fetuses	No. of hematoma	Percentage of hematoma
Group A (control)	168	1	0.59%
Group B (treated)	153	74	48.36%

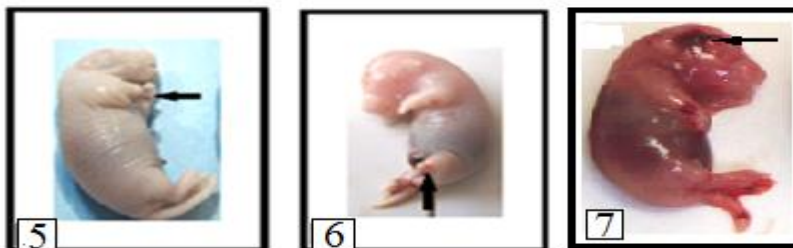
The data are represented as percentage (%)

**Table 6: Effect of HCB on external anomalies in the fetuses on the 20<sup>th</sup> day of gestation.**

Groups during gestation	No. of fetuses examined	Anomalies of limbs			
		Contraction of limbs		Absence of digits	
		No.	%	No.	%
Group A (Control)	168	-	-	-	-
Group B (Treated)	153	4	2.6	6	3.9

The data are represented as percentage (%)

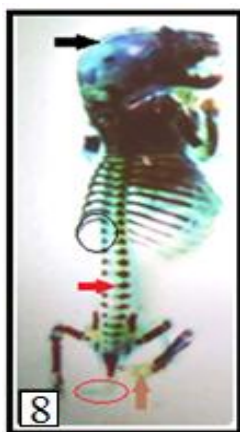



**Fig.5:** A photograph of fetus maternally treated with (100mg/Kg) HCB shows contraction of fore limbs (arrow).  
**Fig.6:** A photograph of fetus maternally treated with (100mg/Kg) HCB shows absent of fingers (oligodactyly) in left hind limb (arrow).  
**Fig. 7:** A photograph of fetuses maternally treated with (100mg/Kg) HCB from (5<sup>th</sup> to 19<sup>th</sup> day of gestation) shows hematoma on the head (arrow) and fore limb.

**Skeletal examination**

Fetuses of the group maternally treated with 100mg/kg HCB showed lack of ossification of roof of the skull, shortness of 13<sup>th</sup> ribs, lack of ossification of metacarpus, caudal vertebra and phalanges, non ossification of metatarsus, phalanges and curved ilium. Lack of 12<sup>th</sup> and 13<sup>th</sup> ribs and lack of ossification of central vertebrae (fig.8) and mandibular hypoplasia were also obvious features.



**Fig. 8:** A photograph of skeletal system of fetus maternally treated with (100mg/kg) HCB from (5<sup>th</sup> to 19<sup>th</sup> day of gestation) shows lack of ossification of roof of the skull (black arrow), lack of 12<sup>th</sup> and 13<sup>th</sup> ribs (black circle), lack of ossification of caudal vertebra (red circle), lack of ossification of central vertebra and non ossification of metatarsus, phalanges (brown arrow).

**Histological studies of fetuses**

Examination of serial transverse sections of the brain, liver and kidney of albino rat fetuses maternally treated with HCB on the 20<sup>th</sup> day of gestation showed some histological changes as fetuses maternally treated with 100mg/Kg HCB there were congested blood vessel in cerebrum as well as fibrosis as well as vacuolization in the matrix of striatum in the cerebrum and degenerated cells. The fetuses maternally treated with 100mg/Kg HCB showed fibrosis, degenerated cell and congested blood vessels in the cerebellum. The liver of fetuses maternally treated with 100mg/Kg HCB showed dilatation that was noticed in the central vein associated with fatty change in some few hepatocytes as well severe dilation and congestion in portal vein with oedema in portal area and dilation in bile duct. Sections of kidney of fetuses maternally treated with 100mg/Kg HCB revealed some histological changes such as proliferation of lining epithelium of glomerular tufts and swelling of the glomeruli while others were shrunken, fatty degeneration, hydropic degeneration, pyknotic nuclei, detached cell of tubules and failure in the connection between the proximal and distal convoluted tubules was detected.

**Oxidative stress investigations during gestation**

**Glutathione reduced (GSH) content**

The treated rat fetuses on the 20<sup>th</sup> day of gestation indicated a marked decrease in cerebrum, cerebellum and liver glutathione content throughout the experiment compared to control fetuses.

**Malondialdehyde**

The treated rat fetuses on the 20<sup>th</sup> day of gestation indicated a marked increase in cerebrum, cerebellum and liver lipid peroxidation content throughout the experiment compared to control fetuses.

**Effects of HCB on albino rat neonates during lactation**

**Fetal mortality**

Total mortality rate of fetuses maternally treated with 100mg/kg HCB was 77.19% compared to control group (table 9).

**Table 9: Effect of HCB on fetal mortality during lactation.**

Groups	Total no. of sacrificed rat	No. of live neonates	No. of dead		mortality rate		
			Before 7 <sup>th</sup> day	After 7 <sup>th</sup> day	Before 7 <sup>th</sup> day	After 7 <sup>th</sup> day	Total mortality rate
Group A (Control)	20	174	-	-	-	-	-
Group B (Treated)	20	114	67	21	58.77%	18.4%	77.19%

The data are represented as percentage (%)

**Growth retardation**

The morphological examination of neonates maternally treated with HCB showed growth retardation represented by decrease in body weight, body length and tail length according to control neonates on the 7<sup>th</sup> day of lactation (table 10).

**Table 10: The body weight, body length and tail length of neonates on 1<sup>st</sup> and 7<sup>th</sup> day of lactation.**

Groups During lactation	Average body wt. of neonates		Average body length of neonates		Average tail length of neonates	
	1 <sup>st</sup> day	7 <sup>th</sup> day	1 <sup>st</sup> day	7 <sup>th</sup> day	1 <sup>st</sup> day	7 <sup>th</sup> day
Group A (control)	3.701 <sup>a</sup> ± 0.030	12.810 <sup>a</sup> ± 0.572	5.576 <sup>a</sup> ± 0.129	7.012 <sup>a</sup> ± 0.199	1.656 <sup>a</sup> ± 0.096	2.641 <sup>a</sup> ± 0.154
Group B (Treated)	3.157 <sup>b</sup> ± 0.154	6.343 <sup>b</sup> ± 0.760	3.666 <sup>b</sup> ± 0.259	5.775 <sup>b</sup> ± 0.400	1.49 <sup>b</sup> ± 0.097	2.229 <sup>b</sup> ± 0.127

Data are expressed as mean ±Standard error

Means with the same latter in the same parameter are not significantly different

F-probability expresses the effect between groups, where P<0.0001 is very highly significant.

The average body weight, body length and tail length of neonates maternally treated with 100mg /Kg HCB from 5<sup>th</sup> of gestation to 6<sup>th</sup> day of lactation was decreased than those of the control group (P<0.0001).

**Effect of HCB on external and internal anomalies in the neonates on 7<sup>th</sup> day of gestation**

In neonates maternally treated with 100mg/Kg HCB the percentages of hematoma is 7.89% (table 11) and limb anomalies were mainly oligodactyly.

**Table 11: Effect of HCB on the percentage of hematoma in neonates on the 7<sup>th</sup> day of lactation.**

Groups	No. of examined neonates	No. of hematoma	Percentage of hematoma
Group A (control)	174	-	-
Group B (control)	114	9	7.89%

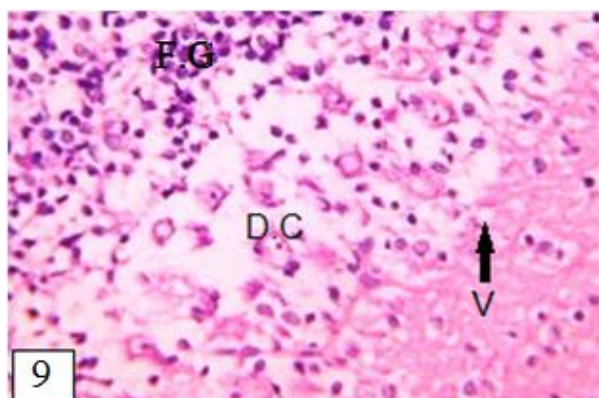
The data are represented as percentage (%)

**Skeletal examination**

The group maternally treated with 100mg/Kg HCB showed shortness of 13<sup>th</sup> right rib and absence of 13<sup>th</sup> rib (fig. 12B). Lack of ossification of caudal vertebra, metatarsus and phalanges.

**Histological studies of neonates on the 7<sup>th</sup> day of lactation**

Examination of serial transverse sections of the brain, liver and kidney of albino rat neonates maternally treated with HCB on the 7<sup>th</sup> day of lactation showed some histological changes as the group maternally treated with 100mg/KgHCB on the 7<sup>th</sup> day of lactation showing pyknotic nuclei in the matrix of striatum in the cerebrum, blood sinusoids and vacuolization as well as degenerated cells in the matrix of striatum in the cerebrum with focal gliosis (fig.9).



**Fig. 9: A photomicrograph of brain of neonates on the 7<sup>th</sup> day of lactation maternally treated with (100mg/Kg) from (5<sup>th</sup> day of gestation to 6<sup>th</sup> day of lactation) shows degenerated cell (D.C) in the matrix of striatum in the cerebrum, focal gliosis (F.G) and vacuolization (V). ( H&E) (80x)**

The group of neonates maternally treated with 100mg/Kg HCB on the 7<sup>th</sup> day of lactation showed degeneration in purkinje cell layer in the cerebellum as well as degeneration in medulla of white matter with vacuolization in molecular layer and degeneration in granular cell layer. The liver of neonates maternally treated with 100mg/KgHCB on the 7<sup>th</sup> day of lactation revealed histopathological changes which appeared as dilation in central vein, destruction of hepatic cells, some hemorrhage in hepatic parenchyma as well as dilation in central vein with dilation in bile ductus, oedema, inflammatory cell infiltration and fatty change in some focal area of hepatocytes. The kidney of neonates maternally treated with 100mg/KgHCB on the 7<sup>th</sup> day of lactation showed detached cells of tubules, proliferation in lining endothelium of the glomerular tufts, fatty degeneration, congestion of blood vessel with destruction tubules, degenerated glomeruli and failure of the junction between the proximal and distal tubules.

**Oxidative stress investigations during lactation:**

**Glutathione reduced (GSH) content:**

The treated rat neonates on the 7<sup>th</sup> day of lactation indicated a marked decrease in cerebrum, cerebellum and liver glutathione content throughout the experiment as compared to control neonates.

## Malondialdehyde

The treated rat neonates on the 7<sup>th</sup> day of lactation indicated a marked increase in cerebrum, cerebellum and liver lipid peroxidation content throughout the experiment as compared to control neonates.

## DISCUSSION

Hexachlorobenzene (HCB) is one of the highly toxic and persistent compounds that are released unintentionally through various man-made chemicals. It is considered as a member of POPs because it is persistent for long periods of time in the environment and found to be hazardous for all living organisms (Mukesh Kumar *et al.*, 2013). It differs from other chlorinated hydrocarbons such as DDT and PCBs in that HCB is not manufactured intentionally as the other compounds were, and therefore, the manufacturing of HCB cannot be stopped or curtailed as readily (Diane Courtney and James Andrews, 1985).

In our study, signs of toxicity of HCB in pregnant rats and mother rats were in the form of reduced weight gain in the gestational period and reduced weight in lactation period. Reduced body weights in the dams were first seen after administration of 100mg/Kg body weight day after day for at least 20 days.

Growth retardation was represented by decreasing fetal body weight, body length and tail length; these changes were dose and time dependent. And these findings are in agreement with Edwards *et al.*, (1991) who suggested that doses of 80mg/Kg/ day for 4 or more days of pregnancy reduced fetal birth weights.

HCB readily passes the placental barrier. Accumulation in fetal tissue has been demonstrated in the rat (Nakashima *et al.*, 1997).

In our study, passing of HCB through placenta caused a decrease in the placental weight compared to the control placenta.

Yoko *et al.*, (1997) strongly suggests that although rat fetuses were very small, a great portion of the HCB that accumulated in dams during pregnancy was postnatally transferred to suckling pups through milk immediately after birth. Further study will be required to clarify the mechanisms which accelerate the metabolism and excretion of lipophilic environmental pollutants and depress their accumulation in the body during pregnancy and lactation.

The morphological changes observed in the present work proved that HCB caused gross malformation, subcutaneous hematoma in different sites, abnormalities in limbs, especially paralysis, absence and shortness of digits during gestation and lactation periods.

In our study fetal skeletal abnormalities observed included defective ossification of ribs, wavy ribs, shortness and asymmetrical ribs. Lack of ossification of skull bones and vertebral column were observed in all fetuses. The major skeletal defects were observed in hind and fore limb bones in the form of complete cartilage. The neonates during lactation showed shortness and asymmetrical ribs and lack of ossification of caudal vertebra, metatarsus and phalanges.

Cripps *et al.*, (1984) and Peters *et al.*, (1982, 1987) suggested that there was severe shortening of digits due to osteoporosis in the bones of hands (phalangeal, carpal, and metacarpal), particularly at the ends.

Our study showed that the passage of HCB through placenta caused a decrease in the number and size of trophoblastic giant cells, cystic degeneration of glycogen cells, degeneration in basal layer and massive hyperemia in the labyrinth interhemal membrane of the placenta.

During gestation and lactation periods we found that the brain of pregnant rats showed focal encephalomalacia and focal plaques formation as well as vacuolization in the matrix of striatum of cerebrum and vacuolization in the medulla of white matter with degeneration in Purkinje cell layer in the cerebellum. The liver shows fatty change in the hepatocytes as well as inflammatory cell infiltration, oedema was detected in the portal area associated with severe dilatation in the portal vein detected in the liver sections. The kidney shows swelling and proliferation in the lining endothelium of the glomerular tufts with swelling and

degeneration of lining epithelium of the tubules with congestion in the blood vessels, and Focal hemorrhages at the corticomedullary portion

In our study HCB across through the placenta into the fetus and caused some histological changes in each of the brain, liver, and the kidney. We observed that, there is congestion of the blood vessels, fibrosisvacuolization in the matrix of striatum in the cerebrum and degenerated cells. Meanwhile the fetuses' cerebellum showed fibrosis, degenerated cells and congestion in the blood vessels in the cerebellum.

While in the lactation period, the brain section showed pyknotic nuclei in the matrix of striatum in the cerebrum, blood sinusoids and vacuole as well as degenerated cells with focal gliosis. In the cerebellum there are degeneration in purkinje cell layer as well as degeneration in medulla of white matter with vocalization in molecular layer and degeneration in the granular cell layer.

In the liver section of fetuses, dilatation was noticed in the central vein associated with fatty change in some few hepatocytes, severe dilation and congestion in portal vein with oedema in portal area and dilation in bile duct. The kidney of fetuses and neonates shows proliferation and swelling of glomeruli, fatty degeneration, hydropic degeneration, pyknotic nuclei, detached cells of tubules, shrinking of glomeruli and failure in the connection between the proximal and distal convoluted tubules was detected.

Our results showed that prenatal exposure to HCB impaired the antioxidative and oxidative status, causing significant increase in the lipid peroxidation in liver and brain compared to control group, while significant decrease in glutathione level was recorded in liver and brain of the treated group.

### CONCLUSION

It is evident that HCB is teratogenic and much care must be given to prevent the increased risk due to exposure and handling such a dangerous material.

### REFERENCES

- [1] Akron, (2010): The Chemical Database. The Department of Chemistry at the University of Akron. <http://ull.chemistry.uakron.edu/erd> and search on CAS number.
- [2] Almeida, M.G.; Fanini, F.; Davino, S.C.; Aznar, A.E.; Koch, O.R. and Barros, S.B.M. (1997): Pro - and - antioxidant parameters of rat liver after short term exposure to hexachlorobenzene. *Hum. Exp. Toxicol., Basingstoke, v.16, p.257-261.*
- [3] Alvarez, L.; Randi, A.; Alvarez, P.; Piroli, G.; Chamson-Reig, A.; V. Lux-Lantos, and Kleimanvde Pisarev, D. (2000): Reproductive effects of hexachlorobenzene in female rats, *J. Appl. Toxicol., 20:81-7.*
- [4] Armitage, P. and Berry, G. (1987): Comparison of several groups In: Blackwell Scientific Publications, Oxford, Pp.186-213.
- [5] ATSDR (Agency for Toxic Substances and Disease Registry), (2002): Toxicological profile for hexachlorobenzene. US Department of Health and Human Services, Public Health Service, Agency for Toxic Substances and Disease Registry, Atlanta, GA.
- [6] Beutler, E.; Duron, O. and Kelly, M.B. (1963): Improved method for the determination of blood glutathione. *J. Lab. Clin. Med. 61: 882-888.*
- [7] Billi de Catabbi, S.; Sterin-Speziale, N.; Fernandez, M.C.; Minutolo, C.; Aldonatti, C. and San Martin de Viale, L. (1997): Time course of hexachlorobenzene-induced alterations of lipid metabolism and their relation to porphyria. *Int. J. Biochem. Cell Biol., Oxford, v.29, p.335-344.*
- [8] BUA (Beratergremium für umweltrelevante Altstoffe der Gesellschaft deutscher Chemiker) (1994): Hexachlorbenzol. *Bericht. Nr. 119, Hirzel Verlag, Stuttgart.*
- [9] Chevrier, J.; Eskenazi, B.; Holland, N.; Bradman, A. and Barr, D.B. (2008): Effects of exposure to polychlorinated biphenyls and organochlorine pesticides on thyroid function during pregnancy. *American Journal of Epidemiology, 168(3):298-310.*
- [10] CHRIS, United States Coast Guard. (1994): Hexachlorobenzene, in chemical hazard response information system (CHRIS), vol 20, *Micromedex Inc, Denver, CO, USA.*
- [11] Courtney, K.D.; Andrews, J.E. and Svendsgaard, D.J. (1979): Hexachlorobenzene (HCB) deposition in maternal and fetal tissues of rat and mouse. I. Chemical quantification of HCB in tissues. *Environ. Res., 19: 1-13.*

- [12] Cripps, D. J.; Peters, H. A.; Gocmen, A. and Do- Gfumici, I. (1984): Porphyria turcica due to hexachlorobenzene: a 20 to 30 year follow-up study on 204 patients. *Brit. J. Dermatol.*, 111:4 13-422.
- [13] Diane Courtney, K. and James E. Andrews, (1985): Neonatal and maternal body burdens of hexachlorobenzene (HCB) in Mice: Gestational exposure and lactational transfer. *Fundamental and Applied Toxicology*, 5: 265-277.
- [14] Edwards, I.R.; Ferry, D.G. and Temple, W.A. (1991): Fungicides and related compounds. In handbook of pesticide toxicology. Hayes, W.j., Jr. and Laws, E.R., Jr. Academic press, new york
- [15] EFSA, (2006): Opinion of the scientific panel on contaminants in the food chain on request from the Commission related to hexachlorobenzene as undesirable substance in animal feed. *The EFSA Journal*, 402: 1 – 49.
- [16] Elissalde, M.H. and Clark, D.E. (1979): Testosterone metabolism by hexachlorobenzeneinduced hepatic microsomal enzymes. *Am. J. Vet. Res.*, 40:1762-6.
- [17] Ferioli, A.; Harvey, C.; de Matteis, F. and Druginduced, (1984): accumulation of uroporphyrin in chicken hepatocyte cultures. *Biochem. J., London*, v. 224, p.769- 777.
- [18] Foster, W.G.; Pentick, J.A.; McMahan, A. and Lecavalier, P.R. (1993): Body distribution and endocrine toxicity of hexachlorobenzene (HCB) in the female rat. *J. appl. Toxicol.*, 13: 79–83.
- [19] Government of Canada. (1993): Canadian Environmental Protection Act- Priority substances list assessment report: Hexachlorobenzene, Ottawa, *Canada Communication Group Publishing*.
- [20] HSDB, Hazardous Substances Data Bank, (2010): National Library of Medicine. <http://toxnet.nlm.nih.gov/cgi-bin/sis/htmlgen?HSDB> and search on CAS number.
- [21] INERIS, (2005): Hexachlorobenzene. Données technico-économiques sur les substances chimiques en France. [http://www.ineris.fr/rsde/fiches/fiche\\_hexachlorobenzene.pdf](http://www.ineris.fr/rsde/fiches/fiche_hexachlorobenzene.pdf)
- [22] IARC, (1979): Monograph of the Carcinogenic Risk of Chemicals to Man. Vol. 20, pp. 155-178.
- [23] IARC, (1979): IARC Monographs on the Evaluation of Carcinogenic Risks to Humans. Some halogenated hydrocarbons, vol 20, WHO, Geneva, Switzerland.
- [24] Kamel, F. and Hoppin, J. (2004): Association of pesticide exposure with neurologic dysfunction and disease. *Environmental Health Perspectives*, 112:950-958.
- [25] McClain, R.M. and Becker, B.A. (1975): Teratogenicity, foetal toxicity and placental transfer of lead nitrate in rats. *Toxicol. Appl. Pharmacol.*, 931: 72-82.
- [26] Mohammad Abdollahi; Akram Ranjbar; Shahin Shadnia; Shekoufeh Nikfar and Ali Rezaie, (2004): Pesticides and oxidative stress: a review. *Med. Sci. Monit.*, 10(6): RA141-147.
- [27] Mukesh Kumar, D.J.; Dinesh Kumar, S.; Kubendran, D. and Kalaichelvan, P.T. (2013): Hexachlorobenzene - Sources, Remediation and Future Prospects. *Int. J. Cur. Res. Rev.*, Vol 05 (01).
- [28] Nakashima, Y.; Ohsawa, S.; Umegaki, K. and Ikegami, S. (1997): Hexachlorobenzene accumulated by dams during pregnancy is transferred to suckling rats durind early lactation. *J. Nutr.*, 127: 648-654.
- [29] Peters, (1977): Double staining of foetal skeletons for cartilage and Bone in:" Methods in prenatal toxicology ". Neu bert,D.; Merkerd, H.J. and Kwasigroch,T.E. *George Thieme, Stuttgart*. 153-154.
- [30] Peters, H.A.; Gocmen, A. and Cripps, D.J. (1982): Epidemiology of hexachlorobenzene-induced porphyria in Turkey: Clinical and laboratory follow-up after 25 years. *Arch. Neurol.*, 39:744-749.
- [31] Peters, H.; Cripps, D. and Gocmen, A. (1987): Turkish epidemic hexachlorobenzene porphyria: A 30-year study. *Ann. NY. Acad. Sci.*, 514:183-190.
- [32] Ohkawa, H.; Ohishi, N. and Yagi, K. (1979) Assay for lipid peroxides in animal tissues by thiobarbituric acid reaction. *Anal. Biochem.*,95: 351–358.
- [33] Satoh, K. (1978): Serum lipid peroxide in cerebrovascular disorders determined by new colorimetric method. *Clin. Chim. Acta.*, 90: 37-43.
- [34] Snell, G.D. (1956): Biology of the laboratory Mouse. The Blakiston company, philadelphia.
- [35] Swackhamer, D. and Hites, R.A. (1988): Occurrence and bioaccumulation of organochlorine compounds in fish from Siskiwit Lake, Isle Royale, Lake Superior. *Environ. Sci. Technol.*, 22: 543–548.
- [36] Vassilopoulou, V. and Georgakopoulous-Gregoriades, E. (1993): Factors influencing the uptake of organochlorines in red mullet (*Mullus barbatus*) from a gulf of Central Greece. *Mar. Poll. Bull.*, 26: 285-287.
- [37] Wagner; Lebring and Österreich, V. (2013): Public statement on the use of the BNN orientation value for hexachlorobenzene (HCB) detected in organic pumpkin seeds from Austria. *Berlin*, 22-10117.
- [38] WHO, (1997): Hexachlorobenzene (Environmental Health Criteria 195), Geneva, international programme on chemical safety.





- [39] Xiaochu Gan.; Haibo Zhou.; Bangjing Zhu.; Xinyao Yu.; Yong Jia.; Bai Sun.; Meiyun Zhang.; Xingjiu Huang.; Jinhuai Liu. and Tao Luo. (2012): A simple method to synthesize graphene at 633 K by dechlorination of hexachlorobenzene on Cu foils: *Elsevier*, 306-310.
- [40] Yoko Nakashima; Saeko Ohsawa; Keizo Umegaki and Sachie Ikegami, (1997): Hexachlorobenzene accumulated by dams during pregnancy is transferred to suckling rats during early lactation. *American Society for Nutritional Sciences*, 0022-3166/97.