

See discussions, stats, and author profiles for this publication at: <https://www.researchgate.net/publication/320881362>

Protective Role of Pomegranate Peel (*Punica granatum* L) against Thioacetamide-Induced cirrhosis in a Rat Model

Research · November 2017

CITATIONS

0

READS

35

3 authors, including:



Adnan Albideri

University of Al-Qadisiyah

14 PUBLICATIONS 1 CITATION

[SEE PROFILE](#)



Shaymaa Hussein

University Of Kufa

2 PUBLICATIONS 0 CITATIONS

[SEE PROFILE](#)

Some of the authors of this publication are also working on these related projects:



Histology,Anatomy [View project](#)



histology [View project](#)



Protective Role of Pomegranate Peel (*Punica granatum* L) against Thioacetamide-Induced cirrhosis in a Rat Model

Adnan W. Al-Bideri¹, Alaauddin S.M.Al-sallami², Shaymaa H.Alsaaedi

¹ collage of medicine, University of Al Qadisiya, Iraq

²Department of Biology, collag of Science, University of Kufa, Iraq

³Department of Biology, collag of Science, University of Kufa, Iraq

Abstract: This study was designed to determine the effects of pomegranate peel on various antioxidant measurements in liver cirrhosis of rats induced by thioacetamide. Fifty-seven male rats aged 13–15 weeks were randomly divided into 15 categories containing 5 rats per category, and were treated with either TAA, PP, or PP plus TAA or Selenium plus TAA or administered with 0.9% physiological saline solution as a control. The hepatoprotective effect of herbs was evaluated by measuring levels of antioxidant marker enzymes such as Glutathione Peroxidase (GSH-Px) and Superoxide Dismutase (SOD) and measurement Malondialdehyde (MDA). The histological studies were also carried out to support the above parameters by using special stain Haemotoxlin & eosin and using immunofluorescent staining to examine the distribution of DDR2 in the liver. The study found that the supplementation of pomegranate peel significantly ($p < 0.05$) reduced the damaging effects on the liver by TAA. GSH, SOD increased in the treatment group, but serum MDA level was declined due to the hepatic injury induced. A comparative histopathological research of the liver between different groups demonstrated that pomegranate peel, drive to normal liver architecture suggesting they may use as a hepatoprotective alternative medication.

Key words: TAA Thioacetamide PP pomegranate peel DDR2 Discoidin Domain Receptor

Introduction:

For long time have been used Herbal products in traditional popular medicine to keep health or to supply remedies for various human diseases (1). Liver disorders, including cirrhosis, and take advantage of the therapeutic strategies used compounds extracted from plants and herbs. (2)

Pharmaceutical compounds existing with formulas interferon, colchicines, penicillamine, and corticosteroids currently available to treat common liver cirrhosis and liver fatty disease, chronic hepatitis, but with either conflicting efficiencies or high occurrence of side effects (3). There are a number of natural compounds extracted from plants provide alternative treatment which is safe and effective options(4). Is constantly being tested, or excerpts from the newly discovered known plant species already on the simulation of human diseases and injuries animal model systems (5). At present, the use of many natural extracts for the treatment of human disorders in the hardware, but unlike the liver (6). So, we still have to examine the role and effectiveness of these extracts in potential liver disease. Extract is obtained from pomegranate peel is one of those in this category, and wait to explore for its role in liver disease.

MATERIALS AND METHODS

Preparation of plant peel extraction: It was placed 50 grams of powder dry pomegranate peel in containers Extraction Thimbles in Alsoxlat Soxhlet extractor device and by the way (7). Added 500 ml of ethyl alcohol concentration of 80% and continued extraction for 24 hours and then taking the extract and put in the electric furnace degree (40 m) and after obtaining a dry extract put in the refrigerator, in order to prepare the concentrations required has thawed dry extract small amounts of solvent and then eased by distilled water, according to the concentrations required.



Animals Experimental

75 male wistar rats weighing (210-290) gram were got from the rats household faculty of medicine, university of Baghdad are used in this experimental. The animals lab were contained in a plastic caged and were maintained on standard pellet diet and tap water and kept at $25 \pm 3^\circ\text{C}$ temperature, 50–60% humidity, and a 12 h light-dark cycle for at least one week before starting the experiment. The caged were embedded with in wooden shelves in the animal household of "Faculty of Science, University of Kufa". The experimental rats were divided into fifteen groups of five animals each.

Preparation of Thioacetamide: we have been prepared thioacetamide (Sigma-Aldrich, Switzerland) stock solution 5 g/L from diluting the pure thioacetamide that was in the crystal form. where TAA diluted in distilled water according quantity that we need and mix well the solution until all the crystal thioacetamide was dissolved. Then, 200 mg/kg body weight was given intraperitoneally (ip) to the rats thrice weekly for 12 weeks. The injection method above was according to the research of (2). Continual exposure to a rat with this quantity of TAA induces changes in its liver pathology from both biochemical and morphological aspects analogous to that of human liver cirrhosis (8) and subsequently applied very often as a good model in experimental studies of this disease.

Experimental Protocol: fifty-seven male rats were randomly divided into five groups, each of which with fifteen rats but each group divided into three category According to the treatment period (one month, two month and three month): "Group 1 (control group) rats were injected intraperitoneally with sterile distilled water (2mL/kg) thrice weekly for (one month, two month and month). Group 2 (hepatotoxic group) rats were administered orally with 1 injected intraperitoneally (ip) with Thioacetamide (TAA) (200 mg/kg) thrice weekly for (one month, two months and three months). The injection protocol above was according to the recommendation of Alshawsh *et al.* (2). Group 3 rats were administered orally with pomegranate peel (400 mg/kg) daily and injected ip with TAA (200 mg/kg) thrice weekly for (one month, two month and month) Groups 4 rats were administered orally with the pomegranate peel (200 mg/kg and 200 mg/kg daily and injected ip with TAA (200 mg/kg) thrice weekly for (one month, two months and three months). Groups 5 rats were administered orally with the selenium (200 mg/kg and 200 mg/kg daily and injected ip with TAA (200 mg/kg) thrice weekly for (one month, two month and month)". (8)

Determination of Serum Glutathione Peroxidase (GSH-Px) : Elisa kits detecting glutathione in serum of rats, it is supplied by BioAssay, United State of America. (9).

Determination of serum Malondialdehyde (MDA): Elisa equipment for rats malondialdehyde. This is provided by BioAssay United State of America (10).

Determination of Serum Superoxide Dismutase (SOD): Elisa kits detecting Superoxide Dismutase in serum of rats, it is supplied by BioAssay, United State of America. (9).



Results:

Table 1: Effect of PP ethanol extract on antioxidants and malondialdehyde at the three periods (one month,two months,three months).

periods treatment	GSH			SOD			MDH		
	One month	Two months	Three months	One month	Two months	Three months	One month	Two months	Three months
Control	5.707±.336	5.685±.297	6.005±.245	.334±.023	.368±.011	.370±.018	5.685±.297	5.707±.336	6.005±.245
TAA200mg/kg	4.269±.719	3.538±.702	3.027±.496	.220±.003	.035±.006	.039±.015	4.269±.719	3.538±.702	3.027±.496
Se 250 mg/kg	4.104±.709	3.822±.532	3.705±.676	.130±.020	.043±.008	.413±.033*	4.104±.709	3.822±.532	3.705±.676
PP 200mg/kg	4.314±.342	3.509±.556	3.824±.536	.041±.007	.059±.007	.202±.025*	4.314±.342	3.509±.556	3.824±.536
PP 400mg/kg	4.404±.866	4.222±.446	6.078±.490*	.243±.056	.143±.033	.359±.081*	4.404±.866	4.222±.446	6.078±.490*
LSD	3.863	3.159	3.621	0.422	0.098	0.248	3.707	3.119	2.990

Means between the Se-treated, low-dose PP-treated 200 mg/kg, and high-dose PP-400 mg/kg had significant differences when compared with the cirrhosis control with *P < 0.05 and compared with the normal control Group 1 with **P < 0.05.

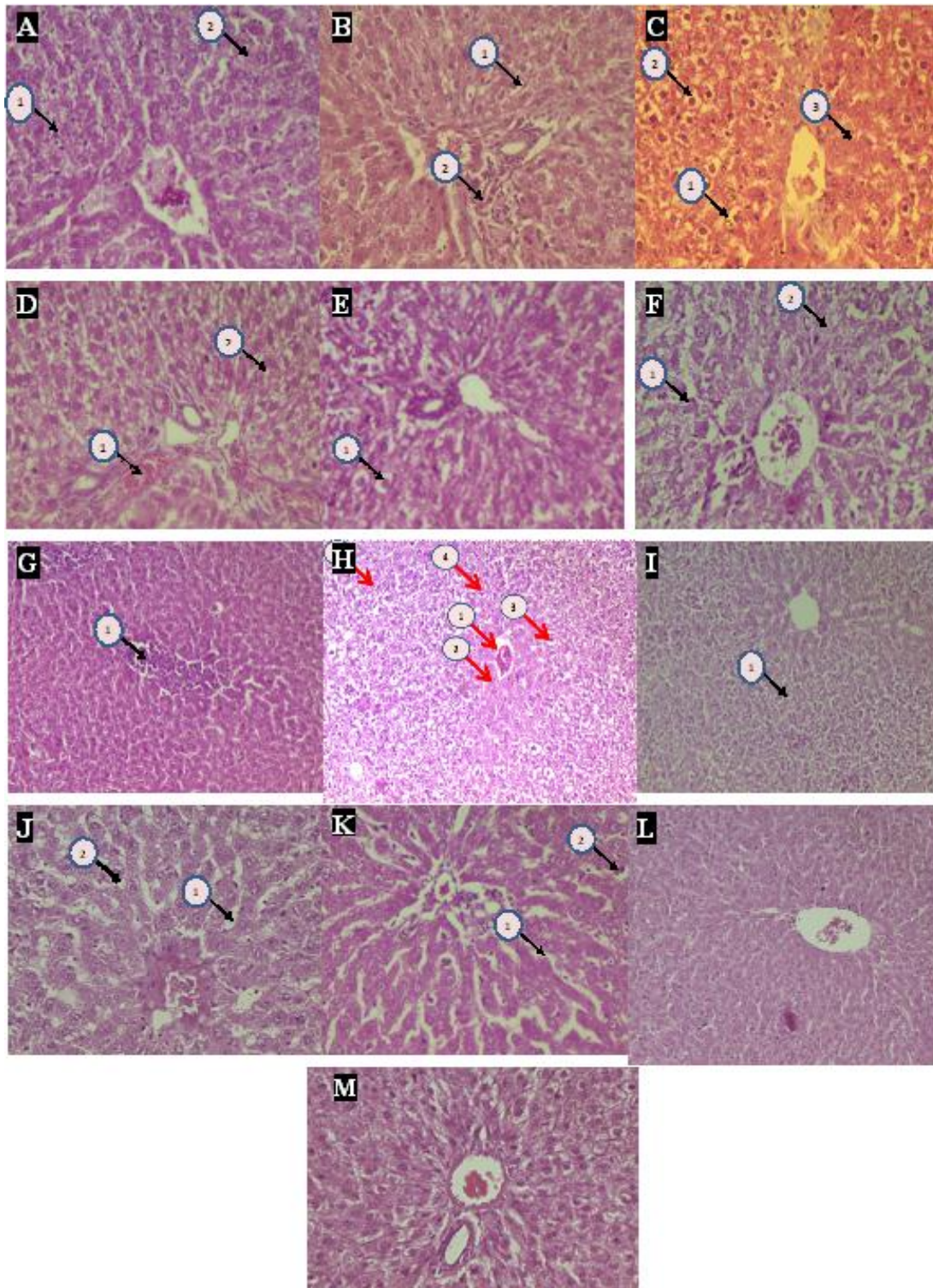


Fig. 1 Histopathological sections of livers sampled from rats in different experimental groups, thioacetamide alone and in combination with pomegranate peel or in combination with selenium on fibrosis grade, in male Sprague–Dawley rats. (M) Negative control, (A,B,C) Thioacetamide treated, injection for (1,2,3 months), respectively (D,E,F) selenium treated (250 mg/kg), orally for (1,2,3 months) respectively, (G,H,I) pomegranate peel treated (200 mg/kg), orally for (1,2,3 months) respectively, (J,K, L) pomegranate peel treated (400 mg/kg), orally for (1,2,3 months) respectively, (H&E stain original magnification 20x).

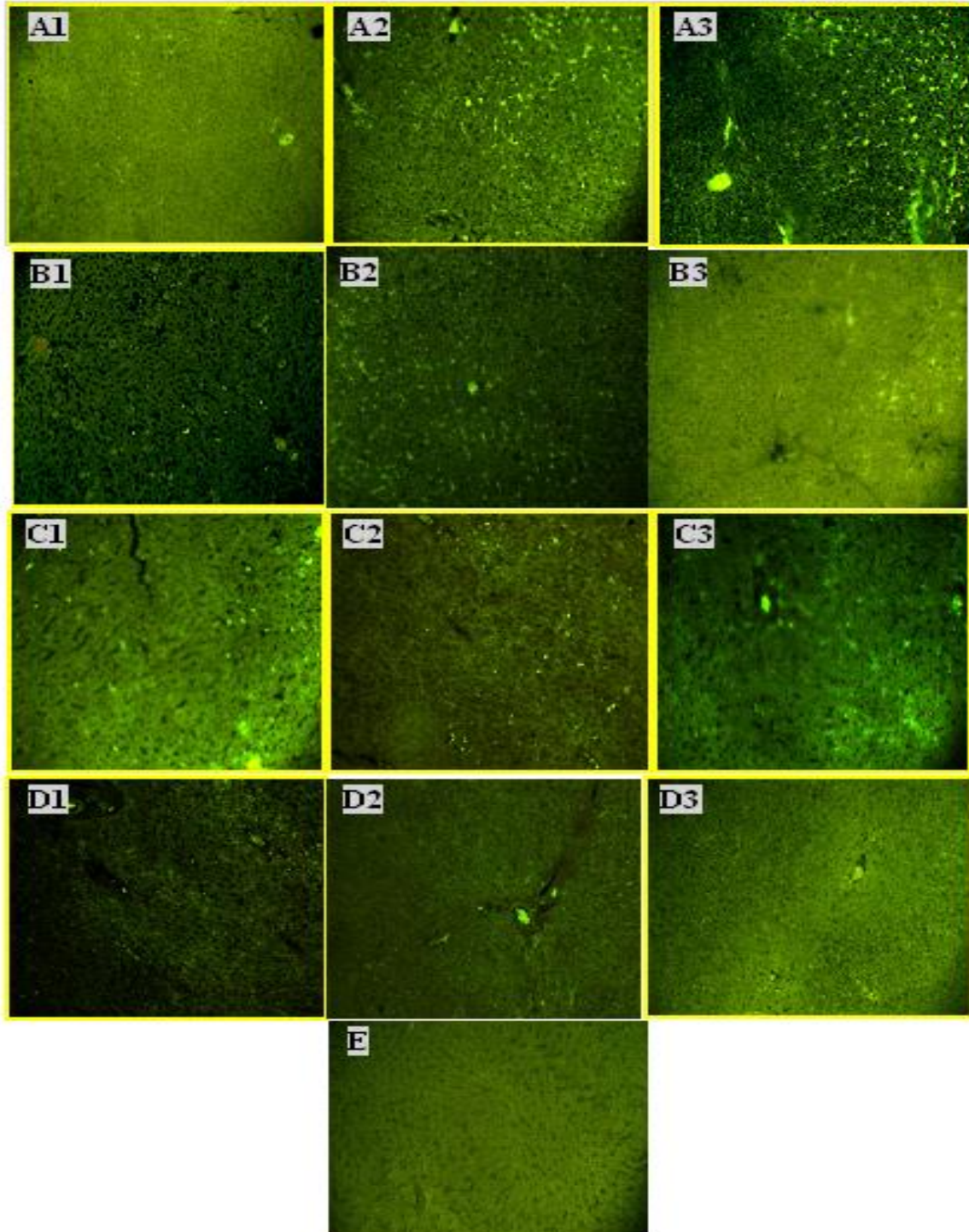


Fig. 2 DDR immunostaining in liver cirrhosis in comparison with treatment with pomegranate peel (PP) or selenium. Basement membranes sinusoid are strongly DDR-positive in groups treated with thioacetamide 200 mg/kg (A). DDR immunostaining becomes weaker, but persists in poorly differentiated in treating with selenium 250 mg/kg and PP 200 mg/kg, even in those with an atypical immunophenotype (B,C). but is scarce or missing in treating with PP 400 mg/kg in liver (D). No immunostaining in liver in control (E).

Histology: In the control group, the livers were obvious of any defect abnormality, and their sections seemed normal with regular cellular departments. The cytoplasm of liver cells intact, and hepatic cells had prominent nucleus, and nucleolus and liver central vein and sinusoidal spaces were normal. In the liver cirrhosis groups, liver tissue has shown many changes which established were as following: three month (1) particulate matter inside



kupffer cells, (2) vacuolar degeneration and (3) and necrosis, two months (1)portal inflammation, and (2) vacuolar degeneration, one month (1) hepatocyte vacuolar degeneration, (2)hepatocyte vacuolar degeneration (3) hepatocyte necrosis, While the therapy groups, which include the group PP400 demonstrated effective treatment as following: three months it is normal tissue, two month prominent sinusoidal dilatation and one month (1)sinusoidal dilatation and (2) vacuolar degeneration and PP200 group demonstrated some changes, there are include: three month vacuolar degeneration,two months (1)hypreosinoplilia, (2) vacuolar degeneration and (3) mononuclear inflammatory infiltrate one month degenerated hepatocytes but selenium group shown some alterations that include:three month (1) hepatocyte vacuolar degeneration and (2) cellular necrotic debris, two month (1)hepatocyte vacuolar degeneration and (2)prominent hepatocyte necrosis and one month prominent venous congestion (1), (2)hepatocyte vacuolar degeneration ,(3) liver cell plates hepatocyte swelling and (4)vacuolar degeneration.

DISCUSSION

Plants applied in the traditional medicine are big interest for liver disorders, as they may serve as potential sources for new curative factors that could be applied in the handling and prevention of hepatic damages. There are a lot of different derivatives anti-oxidant in the plants that are appeared effective antihepatotoxic on experimental liver injury induced by various sorts of models show hepatotoxicants (11).

Thioacetamide is model of liver hepatotoxicant, free radical products causative hepatotoxicity that resulting from its metabolic conversion: "thioacetamide sulfoxide" and "thioacetamide- S, S-dioxide" which attacks microsomal lipids driving to their oxidative degradation " peroxidation", and producing of "reactive oxygen species ROS", such as the H₂O₂, the hydroxyl radical and "super oxide anion O⁻²". ROS affected by the systems of antioxidant defense, when CAT, SOD, and GPX activity that decreases could give rise liver injury, cirrhosis growth, and carcinoma of liver (12). which are considered well-known mechanisms of TAA's action to result liver damage. in spite of that, effective free radical scavengers and antioxidants against lipid peroxy radicals they have been found in plant derived polyphenols(13). the PP extract have capacity to adjust the antioxidant situation of liver or participate with directly in "H₂O₂, super oxide anion O⁻², and the hydroxyl radical" scavenging pathway illustrates the trends in the gauges in respect of retrieving the equilibrium in serum molecules (14). It is known that the toxicity of TAA come after transformation to its bio-activation in the liver and the production of secondary metabolic materials effectively causing oxidative stress inducing by production of ROS (15). This is a success by the depletion of glutathione, reducing SH thiol groups and oxidation of the cell macromolecules, comprising lipids (16). The present study demonstrated significant decreasing in hepatic glutathione level in TAA treated rats. This research correspond with that of (17). and (18). glutathione represents in a reduced form "GSH" and oxidized form "GSSG" but, more than 99% of the total glutathione exists as GSH in tissues (19) where a main function of Glutathione is detoxification of ROS and Stimulate electrophilic compounds (20). Hepatocyte injury induce by TAA is known from during its metabolism to "thioacetamide sulphene and sulphone", by a pivotal process biotransformation intermediates that involve in it cytochrome P450 (21). the denaturation of cellular biomolecules such as lipids, resulting in lipid peroxidation have occurred by highly interactive by TAA metabolites(22). we do not know the mechanisms that participate to the happening of lipid peroxidation and not just involve oxygen free radical generation, but also comprise decrease in the intracellular free radical scavengers with a changes in the cellular antioxidant defense system (23). The dependent mechanism for the decrease in hepatic reduced glutathione content by TAA in our study may be correlating to the suppression of its stimulating enzyme, glutathione reductase "GSH-Rx", by TAA administration(24). Reduced glutathione "GSH" is renewed from oxidized glutathione "GSSG" and NADPH in a reaction stimulated by "GSH-Rx. NADPH",



successively, is stimulated by the hexose monophosphate pathway by a reaction stimulated by "glucose 6 phosphate dehydrogenase G6PD" (25). NADPH, is play role vital for the reduction of GSSG to GSH, that is products via the initial step in the pentose phosphate pathway ,and G6PDH enzyme stimulates these step, therefore deficiency in G6PDH which is being a housekeeping enzyme may be the lower of GSH rate in the liver (26).

The influence of *Punica granatum* on liver enzymes could be referred to the antioxidant effectiveness of its active compounds. Pomegranate juice, peel, seeds – all have a potent antioxidant efficiency due to their active compounds that are electron donors, which can interact with free radicals to transform them to more stable products and finish radical series reaction(27). PP have very high total antioxidant activity because it has proportion of total "flavonoids and polyphenolic" compounds are high. Therefore, the effects antiapoptotic and antioxidant of PP are related to the effects of its polyphenols, such as "flavonoids epicatechin, epigallocatechin gallate, quercetin, luteolin and naringenin, phenolic acids chlorogenic and caffeic acids ellagitannin tannic acid and corilagin" (28). the antioxidant properties of plant polyphenols may appear to interact as electron donors or hydrogen, and its ability to achieve the stability of the single electrons and activities to end the reactions of Fenton as previous studies have shown (29). the polyphenolic elements can remove ROS by they act as good inhibitors of the "N nitrosation reaction" and can stop oxidative injury as a consequence of their ability on it and polyphenolic elements increase the level of glutathione and the actions of "T-GPx" public and "SOD", but it reduces the activity GSR (30). furthermore, some parts in PP such as polysaccharide has a free-radical scavenger properties and how exactly work is still unknown (31).

C-glutamyl cysteine synthetase is critical enzyme in biosynthesis of GSH that can increase production it by flavonoids and ellagic acid (30).

The inhibitory action of *Punica granatum* on lipid peroxidation in rat liver microsomes is associated to the efficiency of phenolic and flavonoid compounds existing in its extract to suppress hepatic oxidative enzymes (cytochrome P450 system) (32). Lipid peroxidation produce, MDA, levels has been found to be reduced significantly upon treatment of infected rats with the ethanolic extract of *Punica granatum* peel, compared with untreated CCl₄-infected rats(33). furthermore, it has been seen that the excess tissue MDA levels due to bile duct ligation (BDL) are also decreased back to control levels by treatment with pomegranate peel extract (PP) in rats (34). therefore, the current results appear that *Punica granatum* peel extract maintains the structural integrity of the hepatocellular membrane and liver cell architecture as proven by our histopathological results. Therefore, it could prevent the loss of liver enzymes into serum and return the liver functions.

REFERENCES

- 1.B. E. Myagmar, E. Shinno, T. Ichiba, and Y. Aniya (2004) .Antioxidant activity of medicinal herb *rhodococcum vitis-idaea* on galactosamine-induced liver injury in rats.*Phytomedicine*, 11(5) , 416–423,.
- 2.M. A. Alshawsh, M. A. Abdulla, S. Ismail, and Z. A. Amin,(2010).Hepatoprotective effects of *orthosiphon stamineus* extract on thioacetamide-induced liver cirrhosis in rats. *Evidence-Based (Boesenbergia rotunda, Boesenbergia pulchella* var *attenuate* and *Boesenbergia armeniaca*)," *Journal of Medicinal Plant Research*, 4 (1),27–32.
- 3.Raison, C. L., Demetrashevili, M., Capuron, L., & Miller, A. H. (2005). Neuropsychiatric adverse effects of interferon- α . *CNS drugs*, 19(2), 105-123.
- 4.Yang, H., Sung, S. H., & Kim, Y. C. (2005). Two New Hepatoprotective Stilbene Glycosides from *Acer mono* Leaves. *Journal of natural products*, 68(1), 101-103.
- 5.Wang, N., Li, P., Wang, Y., Peng, W., Wu, Z., Tan, S., ... & Su, W. (2008). Hepatoprotective effect of *Hypericum japonicum* extract and its fractions. *Journal of Ethnopharmacology*, 116(1), 1-6.

URL: <http://www.uokufa.edu.iq/journals/index.php/ajb/index>

<http://iasj.net/iasj?func=issues&jld=129&uiLanguage=en>

Email: biomgzn.sci@uokufa.edu.iq



- 6.El-Abhar, H. S., Hammad, L. N., & Gawad, H. S. A. (2008). Modulating effect of ginger extract on rats with ulcerative colitis. *Journal of ethnopharmacology*, 118(3), 367-372.
- 7.Harborne, J. B. (1984). Methods of plant analysis. In *Phytochemical methods*(pp. 1-36). Springer Netherlands.
- 8.Chattopadhyay, R. (2003). Possible mechanism of hepatoprotective activity of Azadirachta indica leaf extract: Part II. *Journal of ethnopharmacology*, 89(2), 217-219.
- 9.Burtis, C. A., Ashwood, E. R., & Bruns, D. E. (2012). *Tietz textbook of clinical chemistry and molecular diagnostics*. Elsevier Health Sciences.
- 10.Armstrong, D.; Browne, R. (1994) *Free Rad. Diag. Med.* 366; 43-58.
- 11.Liu, J., Liu, Y., Parkinson, A., & Klaassen, C. D. (1995). Effect of oleanolic acid on hepatic toxicant-activating and detoxifying systems in mice. *Journal of Pharmacology and Experimental Therapeutics*, 275(2), 768-774.
- 12.Poli, G. (2000). Pathogenesis of liver fibrosis: role of oxidative stress. *Molecular aspects of medicine*, 21(3), 49-98.
- 13.Rice-Evans, C. (1995). Plant polyphenols: free radical scavengers or chain-breaking antioxidants?. In *Biochemical Society Symposia* (Vol. 61, pp. 103-116). Portland Press Limited.
- 14.Ajith, T. A., Hema, U., & Aswathy, M. S. (2007). Zingiber officinale Roscoe prevents acetaminophen-induced acute hepatotoxicity by enhancing hepatic antioxidant status. *Food and chemical toxicology*, 45(11), 2267-2272.
- 15.Okuyama, H., Nakamura, H., Shimahara, Y., Araya, S., Kawada, N., Yamaoka, Y., & Yodoi, Y. (2003). Overexpression of thioredoxin prevents acute hepatitis caused by thioacetamide or lipopolysaccharide in mice. *Hepatology*, 37(5), 1015-1025.
- 16.Staňková, P., Kučera, O., Lotková, H., Roušar, T., Endlicher, R., & Červinková, Z. (2010). The toxic effect of thioacetamide on rat liver in vitro. *Toxicology in vitro*, 24(8), 2097-2103.
- 17.Sanz, N., Díez-Fernández, C., Andrés, D., & Cascales, M. (2002). Hepatotoxicity and aging: endogenous antioxidant systems in hepatocytes from 2-, 6-, 12-, 18- and 30-month-old rats following a necrogenic dose of thioacetamide. *Biochimica et Biophysica Acta (BBA)-Molecular Basis of Disease*, 1587(1), 12-20.
- 18.Díez-Fernández, C., Sanz, N., & Cascales, M. (1996). Changes in glucose-6-phosphate dehydrogenase and malic enzyme gene expression in acute hepatic injury induced by thioacetamide. *Biochemical pharmacology*, 51(9), 1159-1163.
- 19.Dickinson, D. A., & Forman, H. J. (2002). Cellular glutathione and thiols metabolism. *Biochemical pharmacology*, 64(5), 1019-1026.
- 20.Han, D., Canali, R., Rettori, D., & Kaplowitz, N. (2003). Effect of glutathione depletion on sites and topology of superoxide and hydrogen peroxide production in mitochondria. *Molecular pharmacology*, 64(5), 1136-1144.
- 21.Okuyama, H., Nakamura, H., Shimahara, Y., Araya, S., Kawada, N., Yamaoka, Y., & Yodoi, Y. (2003). Overexpression of thioredoxin prevents acute hepatitis caused by thioacetamide or lipopolysaccharide in mice. *Hepatology*, 37(5), 1015-1025.
- 22.Cheng Haung W, Yannjan C, Tsung Hsing L, Yi-Shen C, Bruno J, Kuo Sheng H, Chengnan H, Jong Kalg L.(2004).Protective effect of MDL 28170 against thioacetamide induced acute liver failure in mice". *J. Biomed Sci* ,11, 571 - 578.
- 23.Abul, H., Mathew, T. C., Dashti, H. M., & AL-BADER, A. (2002). Level of Superoxide Dismutase, Glutathione Peroxidase and Uric Acid in Thioacetamide-Induced Cirrhotic Rats. *Anatomia, histologia, embryologia*,31(2), 66-71.
- 24.Akbay, A., Çinar, K., Uzunalimoglu, Ö., Eranil, S., Yurdaydin, C., Bozkaya, H., & Bozdayi, M. (1999). Serum cytotoxin and oxidant stress markers in N-acetylcysteine treated thioacetamide hepatotoxicity of rats. *Human & experimental toxicology*, 18(11), 669-676.



25. Ammon, H. P., Grimm, A., Lutz, S., Wagner-Teschner, D., Handel, M., & Hagenloh, I. (1980). Islet glutathione and insulin release. *Diabetes*, 29(10), 830-834.
26. Frederiks W, Bosh K D E, Jong J , Noorden C.(2003). Posttranslational regulation of glucose- 6- phosphate dehydrogenase activity in (pre) neoplastic lesions in rat liver . *J. Hist. Cyto.*, 51, 105 – 112.
27. Singh, R. P., Chidambara Murthy, K. N., & Jayaprakasha, G. K. (2002). Studies on the antioxidant activity of pomegranate (*Punica granatum*) peel and seed extracts using in vitro models. *Journal of agricultural and food chemistry*, 50(1), 81-86.
28. Lansky, E. P., & Newman, R. A. (2007). *Punica granatum* (pomegranate) and its potential for prevention and treatment of inflammation and cancer. *Journal of Ethnopharmacology*, 109, 177–206.
29. Bishayee, A., Bhatia, D., Thoppil, R. J., Darvesh, A. S., Nevo, E., & Lansky, E. P. (2011). Pomegranate-mediated chemoprevention of experimental hepatocarcinogenesis involves Nrf2-regulated antioxidant mechanisms. *Carcinogenesis*, 32(6), 888–896.
30. Moskaug, J., Carlsen, H., Myhrstad, M. C., & Blomhoff, R. (2005). Polyphenols and glutathione synthesis regulation. *The American Journal of Clinical Nutrition*, 81, 277S–283S.
31. Route, S., & Banerjee, R. (2007). Free radical scavenging, anti-glycation and tyrosinase inhibition properties of a polysaccharide fraction isolated from the rind from *Punica granatum*. *Bioresource Technology*, 98, 3159–3163.
32. Ajaikumar, K. B., Asheef, M., Babu, B. H., & Padikkala, J. (2005). The inhibition of gastric mucosal injury by *Punicagranatum L.* (pomegranate) methanolic extract. *Journal of ethnopharmacology*, 96(1), 171-176.
33. Osman MM, Ahmed S. Mahfouz S.(2011) Biochemical studies on the Hepatoprotective effects of Pomegranate and Guava ethanol extracts. *New York Science J.*,4, 27-41.
34. Toklu, H. Z., Sehirli, O., Sener, G., Dumlu, M. U., Ercan, F., Gedik, N., & Gökmen, V. (2007). Pomegranate peel extract prevents liver fibrosis in biliary-obstructed rats. *Journal of Pharmacy and Pharmacology*, 59(9), 1287-1295.