



SCIENTIFIC  
EVENTS GATE

# The International Innovations Journal of Applied Science

Journal homepage: <https://ijias.eventsgate.org/ijias>

ISSN: 3009-1853 (Online)



## Effect of hepatoprotective of aqueous extract of *Ganoderma lucidum* against ketoprofen-induced damage in male rats.

Eda M. A. Alshailabi<sup>1\*</sup> and Heba M. Suleiman<sup>2</sup>

<sup>1,2</sup> Zoology Department, Omar Al-Mukhtar University, El Beida, Libya.

### ARTICLE INFO

#### Article history:

Received 26 Feb. 2024

Revised 16 Apr. 2024,

Accepted 7 May. 2024,

Available online 15 Jul. 2024

#### Keywords:

ketoprofen

*Ganoderma lucidum*

Liver

Histopathology

Rats

### ABSTRACT

This study's objective was to assess the protective impact of an aqueous extract of *G. lucidum* against ketoprofen-induced liver damage in male albino rats. Twenty-eight healthy adult male albino rats were divided into four groups (7 rats in each). Group 1: normal control group; Group 2: rats were given ketoprofen (50mg/kg body weight) daily for two weeks; Group 3: rats were given *G. lucidum* (300mg/kg body weight) daily for four weeks, and Group 4: rats were given ketoprofen (50mg/kg body weight) daily for two weeks, then were given *G. lucidum* (300mg/kg body weight) daily for four weeks. The histological result of the liver of rats treated by ketoprofen showed degenerating hepatocytes, widened with congested central vein with inflammatory cell infiltration, necrotic areas, widened with congested portal vein, thickening wall of central vein enclosed by fibrotic area, and sever haemorrhage. Whereas, the rats which treated by therapeutic dosages showed improved of hepatic architecture with hepatocytes structures, normal sinusoids, minimal congested central vein, improved in the portal area with few inflammatory cell infiltrations, normal sinusoids, and minimal congested portal vein. In conclusion, this study shows that the *G. lucidum* has protective effects against ketoprofen induced hepatic injury in adult male albino rats.

specially with over does (Kelany and Abdallah, 2016).

### 1. Introduction

Many research seemed in the last years about the harmful result of non-steroidal anti-inflammatory drugs (NSAIDs) on the liver and heart (Tomic et al., 2008 and Alshailabi, 2016). Ketoprofen (KP) is a NSAIDs and effective in analgesic of pain, anti-inflammatory and treating fever (Lu et al., 2004 and Akural et al., 2009). It is most frequently prescribed for muscle pain, tissues damage, joints aching (Hiller et al., 2006). Additionally, KP hinders cyclooxygenases (COX) enzymes thus hinders prostaglandin synthesis (Sommerauer et al., 2001 and Hamdani et al., 2015). As KP widely used in treatment of several inflammatory illnesses, is found to make hepatotoxicity

The traditional medication use of *G. lucidum* for indorsing health and permanency is fine recognized in Asian nations, which connecting improved vital energy, heart functions, augmented brain function, and antiaging possessions (Wasser et al., 2005 and Wang et al., 2017). The potential physiological and medical benefits of *G. lucidum*, which have been used traditionally and are still being made, provide support for the safety of bioactive, which include medications, herbal remedies, and health foods. (VanderMolen et al., 2017 and Meneses et al., 2023). Besides, *G. lucidum* has antioxidant, antiaging activities, anticancer, immunomodulatory anti-inflammatory, and antidiabetic, also it has protective effects of liver and heart damage (Ahmad et al., 2023). The frequency of liver diseases is currently increasing worldwide, demanding the pressing expansion of preventive and treatment strategies. Where in

\* Corresponding author.

E-mail address: [eda.muftah@omu.edu.ly](mailto:eda.muftah@omu.edu.ly)

This work is licensed under a [Creative Commons Attribution](https://creativecommons.org/licenses/by/4.0/)

4.0 International License.



recent years, community attention in natural and other treatments have augmented significantly in many countries, with the increasing use of medicinal plants and herbal medicines. Thus, the purpose of this study was to assess the impact of aqueous extract of *G. lucidum* against ketoprofen-induced liver damage in male albino rats.

## 2. Methodology

- Chemical materials:

- Ketoprofen (50mg) was purchased from the European Egyptian pharmaceutical industries.
- *G. lucidum* powder (70g) was purchased from the DXN pharmaceutical SDN.BHD (Malaysia).

- Experimental animals:

At this investigation, twenty-eight adult male albino rats weighing between 150 and 200 grams on average were procured from the central animal house at Zoology department of Omar Al-Mukhtar University. Rats were housed in cages with a good moisture and ventilated at room temperature, and were acclimatized under observation for a duration of four weeks prior to the start of the trial for adaptability. The animals were given unlimited water and regular rat food. The care and use of laboratory animals was conducted in compliance with institutional protocols for all treatments.

- Design experimentation:

## 3. Results and discussion

The liver sections of the NC and GL groups had a lobular architecture that was usual (fig. 1 & 2), Hepatic sinusoids are formed when hepatocytes radiate from the central vein and form anastomosing plates of liver cells that are divided from one another by vascular channels. Moreover, in rats given the KP daily for 2 weeks, the histological preparations of the liver showed degenerating hepatocytes, dilated congested central vein with inflammatory cell infiltration, and necrotic areas (Fig. 3). Besides,

Twenty-eight albino rats were divided into four groups at random, as follows:

Group 1: Normal control group (NC) n = 7, which preserved in typical laboratory settings with given distilled water.

Group 2: *G. lucidum* (GL) n = 7, the GL was given to rats at a dosage of 300mg/kg body weight orally (Hossain et al., 2015) daily for four weeks.

Group 3: Ketoprofen group (KP) n = 7, Rats were given KP orally at a dose of 50 mg/kg body weight (Fadhi & HJebur, 2020) every day for a duration of two weeks.

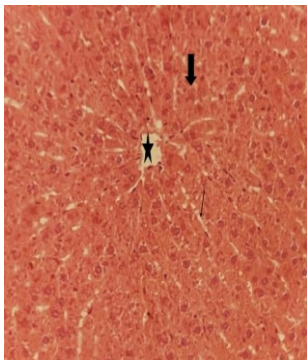
Group 4: The therapeutic group (KP + GL) n = 7, animals received KP at a dosage of 50mg/kg body weight by oral gavage every day for two weeks, after two weeks of ketoprofen dose, the animal were given the GL at a dose of 300mg/kg body weight by oral gavage every day for four weeks.

- Tissue preparation:

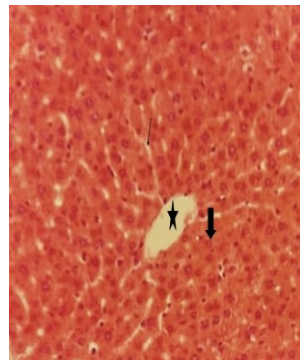
A specimen from the liver of each animal were removed washing in saline solution of 0.9 % NaCl, and fixed in 10% formalin, patted in graded alcohol, xylene and embed in paraffin wax after that were serially sectioned (5 $\mu$  thickness) by using microtome (Lillie, 1954), and stained with hematoxylin and eosin (H & E) using standard procedures, finally sections were examined under light microscope (Bancroft and Stevens, 1982).

dilated congested portal vein, central vein wall thickening encircled by a region of fibrosis, inflammatory cell infiltration, and necrotic areas (Fig.4). Figure (5) shows that the degenerating hepatocytes with vacuolated cytoplasm, haemorrhage, and inflammatory cell infiltration. Also, the liver tissues showed loss of the hepatic architecture accompanied by hydropic oedema and hepatocyte degeneration with kariorrhxisis nuclei in some cells, sever haemorrhage, and inflammatory cell infiltration were seen in figure (6). On the other hand, the liver tissues of rats which treated by therapeutic

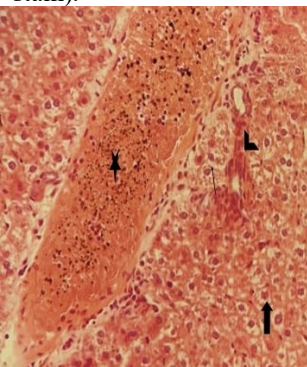
dosages showed improved of hepatic architecture with hepatocytes structures, normal sinusoids, and minimal congested central vein (Fig. 7). Moreover, improved in the portal area with few inflammatory cell infiltrations, normal sinusoids, and minimal congested portal vein (Fig.8).



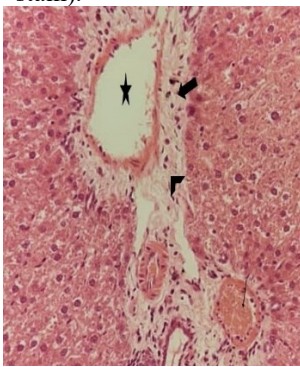
**Figure 1:** T.S. of NC rats' liver tissue with a normal central vein and lobular architecture (star), hepatic sinusoids (thin arrow), and architecture of hepatocytes (thick arrow) (X400, H&E stain).



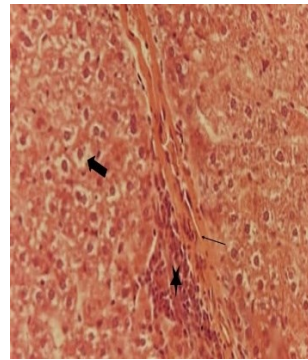
**Figure 2:** T.S. of GL rats' liver tissue with a normal central vein and lobular architecture (star), hepatic sinusoids (thin arrow), and architecture of hepatocytes (thick arrow) (X400, H&E stain).



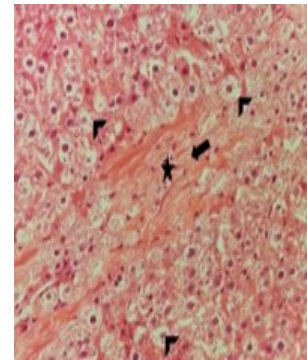
**Figure 3:** T.S. of the KP rats' liver tissue demonstrating deteriorating hepatocytes (thick arrow), dilated, clogged central vein containing an infiltrate of inflammatory cells (star), and necrotic areas (thin arrow) (X400, H&E stain).



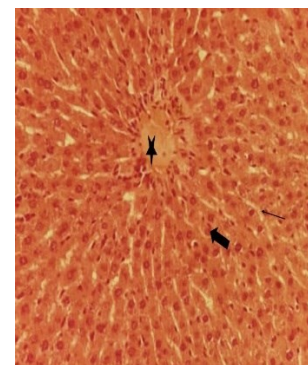
**Figure 4:** T.S. of KP rats' liver tissue displaying a dilated, clogged portal vein (thin arrow), central vein wall thickening (star) encircled by a region of fibrosis (head arrow), inflammatory cell infiltration (thick arrow), and necrotic areas. (X400, H&E stain).



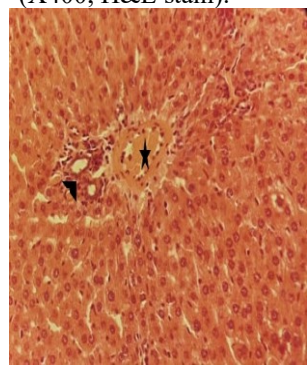
**Figure 5:** T.S. of the KP rats' liver tissue demonstrating, degenerating hepatocytes with vacuolated cytoplasm (thick arrow), haemorrhage (thin arrow), and inflammatory cell infiltration (star) (X400, H&E stain).



**Figure 6:** T.S. of the liver tissue of KP rats exhibiting hydropic oedema, degenerating hepatocytes, and loss of hepatic architecture with kariorrhxis nuclei in some cells (head arrows), sever haemorrhage (thick arrow), and inflammatory cell infiltration (star) (X400, H&E stain).



**Figure 7:** T.S. of the (KP + GL) rats' liver tissue demonstrating enhanced hepatic architecture with hepatocyte structures (thick arrow), normal sinusoids (thin arrow), and minimal congested central vein (star) (X400, H&E stain).



**Figure 8:** T.S. of the (KP + GL) rats' liver tissue showing, improved in the portal area with few inflammatory cell infiltrations (head arrow), normal sinusoids, and minimal congested portal vein (star) (X400, H&E stain).

The use of NSAIDs represents a significant issue because of its adverse effects, which primarily affect the digestive system (Alshailabi, 2016). Additionally, the pharmacologic action of NSAIDs is linked to the widely acknowledged inhibition of prostaglandin production as COX-2 (El-Shinnawy et al., 2014). Results obtained in the present study showed histopathological changes in treated rats by KP comprising



necrotic regions, a dilated, congested portal vein, thickening of the central vein's wall encircled by fibrotic area, degenerating hepatocytes, and dilated, congested central vein with inflammatory cell infiltration, hydropic swelling with kariorrhxis nuclei in some hepatic cells and sever haemorrhage. These were discovered to be in line with Khalil et al. (2023) and El-Feky et al. (2018) they said the KP works through stopping arachidonic acid metabolism through the COX pathway and declining the NSAIDs inhibit prostaglandin's protective effects by activating the COX pathway, lipoxygenase pathway, and raising the production of leukotrienes, which act as mediators of inflammation. Moreover, Donati et al. (2016) showed the KP caused the increased risk of hepatotoxicity (acute and serious liver injury). KP has also been related with hepatic side effects reaching from symptomless promotions in serum aminotransferase levels and hepatitis with bitterness to fulminant hepatic failure and death (Sriuttha et al., 2018). Moreover, Kobayashi, et al. (2001) & Alshailabi (2016) revealed that, inflammatory cells are a primary source of inflammatory mediators and announcement strong reactive oxygen species (ROS) such as superoxide, hydrogen peroxide, and myeloperoxidase produced oxidants as a result they cause lipid peroxidation. Where these ROS are particularly cytotoxic and can trigger tissue injury. Furthermore, high KP dosages might produce hepatotoxicity and necrosis because the liver's metabolism of the drug is concentrated, producing metabolites that are both liposoluble and hydrosoluble. (El-Feky et al., 2018).

Whereas, the rats which treated by therapeutic dosages (KP + GL) showed improved of hepatic architecture with hepatocytes structures, normal sinusoids, minimal congested central vein, improved in the portal area with few inflammatory cell infiltrations, normal sinusoids, and minimal congested portal vein. These results agreement with Ahmad et al. (2023) they discovered that *G. lucidum* protects the liver via a variety of mechanisms, such as altering Phase I and II

liver enzymes, suppressing  $\beta$ -glucuronidase, having antifibrotic and antiviral effects, controlling nitric oxide production, preserving hepatocellular calcium homeostasis, immunomodulatory activity, and scavenging free radicals. However, demonstrated that the *G. lucidum* extract influences the IL-1 $\beta$  protein expression in the liver tissues, which in turn lowers the expression of the pro-inflammatory TNF- $\alpha$  and IL-6 proteins (Meneses et al., 2023). Also, Johra et al. (2023) found that the *G. lucidum* extracts have shown strong free radical scavenging properties, indicating their antioxidant potential and potential to improve oxidative stress-related illnesses such liver and stroke. It therefore has the potential to reduce elevated liver markers, thereby reducing oxidative stress related to hepatic damage and increasing the hepatoprotective genetic factor.

#### 4. Conclusions

The present results obviously determine that the taken of KP is causes of histopathological variations in the hepatic tissues of the albino rats. In addition, that the *G. lucidum* has protective roles against of the KP-induced hepatic damage in male albino rats.

#### References

- Ahmad, M F., Ahmad, F. A., Zeyauallah, M., Alsayegh, A. A., Mahmood, S. E., AlShahrani, A. M., Khan, M. S., Shama, E., Hamouda, A., Elbendary, E. Y., & Attia, K. A. H. A. (2023). *Ganoderma lucidum*: Novel insight into hepatoprotective potential with mechanisms of action. *Nutrients*, 15, 1874, 1-22. <https://doi.org/10.3390/nu15081874>.
- Akural, E. I., Jarvimaki, V., Lansineva, A., Niinimaa, A., & Alahuhta, S. (2009). Effects of combination treatment with ketoprofen 100 mg + acetaminophen 1000 mg on postoperative dental pain: a single-dose 10-hour randomized double-blind active and placebo-controlled clinical trial. *Clinical Therapeutics*, 31(3), 560-568. <https://doi.org/10.1016/j.clinthera.2009.03.017>.
- Alshailabi, E. M. A. (2016). Antioxidant properties of indole-3-carbinol on hepatotoxicity induction in experimental animals. *Global Libyan Journal*, 8,1-8. <https://doi.org/10.37376/1570-000-008-003>.

- Bancroft, J., & Stevens, A. (1982). Second ed. Churchill Livingstone; N.Y: *Theory and Practice of Histological Techniques*.
- Donati, M., Conforti, A., Lenti, M. C., Capuano, A., Bortolami, O., Motola, D., Moretti, U., Vannacci, A., Rafaniello, C., Vaccheri, A., Arzenton, E., Roberto Bonaiuti, R., Sportiello, L., & Leone, R. (2016). Risk of acute and serious liver injury associated to nimesulide and other NSAIDs: data from drug-induced liver injury case-control study in Italy. *British Journal of Clinical Pharmacology*, 82, 238–248. <https://doi.org/10.1111/bcp.12938>.
- El-Feky, A. M., Elbatany, M. M., Aboul Naser, A. F., & Hamed, M. A. (2018). A therapeutic insight of carbohydrate and fixed oil from *Plantago ovata* L. seeds against ketoprofen-induced hepatorenal toxicity in rats. *Bulletin of the National Research Centre*. 42(28), 1-16. <https://doi.org/10.1186/s42269-018-0031-4>.
- El-Shinnawy, N. A., Abd-Elmageid, S. A., & Alshailab, E. M. A. (2014). Evaluation of antiulcer activity of indole-3-carbinol and/or omeprazole on aspirin-induced gastric ulcer in rats. *Toxicology and industrial health*, 30(4), 357-375. <https://doi.org/10.1177/0748233712457448>.
- Fadhi, S. R., & Jebur, H.B. (2020). The intraperitoneal ketoprofen-histopathological induced alterations in the Wistar rat kidneys. *Indian Journal of Forensic Medicine & Toxicology*, 14 (4), 2891-2895. <https://doi.org/10.37506/ijfmt.v14i4.12029>
- Hamdani, D. A., Javeed, A., Ashraf, M., Nazir, J., Ghafoor A., & Yousaf M. S. (2015). Effects of ketoprofen on cellular immune responses in mice. *Pakistan Journal of Zoology*. 47(2), 551-557.
- Hiller, A., Meretoja, O. A., Korpela, R., Piiparinen, S., & Taivainen, T. (2006). The analgesic efficacy of acetaminophen, ketoprofen, or their combination for pediatric surgical patients having soft tissue or orthopedic procedures. *Anesth Analg*, 102(5), 1365-71. <https://doi.org/10.1213/01.ane.0000204278.71548.bf>
- Hossain, S., Bhowmick, S., Islam, S., Rozario, L., Jahan, S., Hassan, M., Sarkar, M., Choudhury, B. K., Ahmed, S. & Shahjalal H. (2015). Oral Administration of *Ganoderma lucidum* to lead-exposed rats protects erythrocytes against hemolysis: implicates to anti-anemia. *Evidence-Based Complementary and Alternative Medicine*, 2015, 1-9. <https://doi.org/10.1155/2015/463703>.
- Johra, F. T., Hossain, S., Jain, P., Bristy, A. T., Emran, T., Ahmed, R., Sharker, S. M., Bepari, A. K., & Reza, H. M. (2023). Amelioration of CCl4-induced oxidative stress and hepatotoxicity by *Ganoderma lucidum* in Long Evans rats. *Scientific Reports*, 13(1), <https://doi.org/10.1038/s41598-023-35228-y>.
- Kelany, M. E., & Abdallah, M. A. (2016). Protective effects of combined  $\beta$ -caryophyllene and silymarin against ketoprofen-induced hepatotoxicity in rats. *Canadian Journal of Physiology and Pharmacology*, 49(7), <https://doi.org/10.1139/cjpp-2015-0607>.
- Khalil, K. A., Alzubaidy, M. H., & Mousa, Y. J. (2023). Effect of xylazine administration on ketoprofen toxicity in mice. *Egyptian Journal of Veterinary Sciences*, 54(5), 983-996. <https://doi.org/10.21608/EJVS.2023.204616.1482>.
- Kobayashi, H., Gil-Guzman, E., & Mahran, A. M. (2001). Quality control of reactive oxygen species measurement by luminoldependent chemiluminescence assay. *Journal of Andrology*, 22(4), 568-574.
- Lillie, R.D. (1954). *Histopathological techniques and practical histochemistry*. Mc Graw-Hill. U.S.A.
- Lu, W., Zhang, Q., Zheng, L., Wang, H., Li, R., Zhang, L., Shen, W., & Tu X. (2004). Antipyretic, analgesic and anti-inflammatory activities of ketoprofen  $\beta$ -Cyclodextrin inclusion complexes in animals. *Biological and Pharmaceutical Bulletin*, 27(10), 1515-1520. <https://doi.org/10.1248/bpb.27.1515>.
- Meneses, M. E., Martínez-Carrera, D., Ibáñez, L. G., Torres, N., Sa´nchez -Tapia, M., Ma´rquez-Mota, C., Rendón, G., Mitz, V., Morales, A., Tello-Salgado, I., & Tovar, A. R. (2023). Effects of Mexican *Ganoderma lucidum* extracts on liver, kidney, and the gut microbiota of Wistar rats: A repeated dose oral toxicity study. *PLoS ONE*, 18(4), e0283605. <https://doi.org/10.1371/journal.pone.0283605>.
- Sommerauer, M., Ates, M., Guhring, H., Brune, K., Amann, R., & Peskar, B. A. (2001). Ketoprofen induced cyclooxygenase inhibition in renal medulla and platelets of rats treated with caffeine. *Pharmacology*, 63(4), 234-239. <https://doi.org/10.1159/000056139>.
- Tomic, Z., Milijasevict, B., Sabot, A., Dusan, L., Jakovljevict, V., Mikovi, M., Majda, S., & Vasovic, V. (2008). Diclofenac and ketoprofen liver toxicity in rat. *European Journal of Drug Metabolism and Pharmacokinetics*, 33(4), 253-260. <https://doi.org/10.1007/BF03190881>.
- VanderMolen, K. M., Little, J. G., Sica, V. P., El-Elimat, T., Raja, H. A., Oberlies, N. H., Baker, T. R., & Mahony, C. (2017). Safety assessment of mushrooms in dietary supplements by combining analytical data with *in silico* toxicology evaluation. *Food and Chemical Toxicology*, 103(4), 133–147. <https://doi.org/10.1016/j.fct.2017.03.005>.
- Wang, J., Cao, B., Zhao, H. & Feng, J. (2017). Emerging Roles of *Ganoderma Lucidum* in Anti-Aging. *Aging and Disease*, 8(6), 691-707. <https://doi.org/10.14336/AD.2017.0410>.

Wasser, S.P., Coates, P., Blackman, M., Cragg, G., Levine, M., Moss, J. & White, J. (2005) Reishi or Lingzhi (*Ganoderma lucidum*). In: Encyclopedia of Dietary Supplements, Marcel Dekker, New York, 680-690.