

The Protective Effects of Indole-3-carbinol on Stomach Injury in Rats

Eda M.A. Alshailabi

Zoology Department, Science Faculty, Omar Al-Moukhtar University,
El Beida , Libya.

Correspondence author: qtuby2014@gmail.com

Abstract

The objective of this research was to analyze the protective effect of indole-3-carbinol against the stomach injury induced by acetylsalicylic acid. Male rats were randomly divided into eight groups of six animals in each group. Control group, OMP group, I3C group, OMP+I3C group, AA group, AA+OMP group, AA+I3C group, and AA+OMP+I3C group. The control rats were received distilled water and the experimental rats were received AA at a dose of 500 mg/kg body weight, OMP at a dose of 20 mg/kg body weight, and I3C at a dose of 50 mg/kg body weight either alone or in combination with each other, orally for seven consecutive days. Results of the present study showed ulcer protection in indole-3-carbinol treated rats was confirmed by histoarchitecture, which was comprised of the reduced size of ulcer crater and restoration of mucosal epithelium. Thus, reduced neutrophil infiltration, antiapoptotic and antioxidant action have a pivotal role in the gastroprotective effect of indole-3-carbinol.

Keywords: Histopathological, Stomach, Acetylsalicylic acid, Indole-3-carbinol, rats.

Introduction:

The basic physiopathological of gastric ulcer results from an imbalance between some endogenous aggressive factors [hydrochloric acid, pepsin, refluxed bile, leukotrienes, reactive oxygen species] and cytoprotective factors, which include the function of the mucus-bicarbonate barrier, surface-active phospholipids, prostaglandins, mucosal blood flow, cell renewal and migration, nonenzymatic and enzymatic antioxidants, and some growth factors (1).

Acetylsalicylic acid (AA), is a drug, often used as an analgesic to relieve minor aches and pains, as an antipyretic to reduce fever, and as an anti-inflammatory medication. Despite the cardiovascular benefits of acetylsalicylic acid, potential gastrointestinal harm has been noted. The main undesirable side effects of AA are gastrointestinal irritation, ulcers, and stomach bleeding (2).

Omeprazole (OMP), like a proton pump inhibitor (PPI), offered a fairly protected gastric mucosa and has been widely used as an acid inhibitor agent for the treatment of disorders related to gastric acid secretion but clinical evaluation of this drug has shown relapse in the long run, side effects and drug interactions (3). The mechanism of action of Omeprazole is such that it binds very specifically to a single subunit of the H^+ , K^+ ATPase at the secretory surface of the parietal cell and inactivates it, and it reduces acid secretion regardless of the source of secretory stimulation (1). Oxidative stress plays important role in the pathogenesis of various diseases including gastric ulcers, with antioxidants being reported to play a significant role in the protection of gastric mucosa against various necrotic agents (4).

Antioxidants could help to protect cells from damage caused by oxidative stress and enhanced the body's defense systems against degenerative diseases. Thus, there is an urgent need to identify more effective and safe antiulcer agents. In this context, the use of medicinal plants for the prevention and treatment of different pathologies is in continuous expansion worldwide (5). Natural products are gaining space and importance in the pharmaceutical industry as well as inspiring the search for new potential sources of bioactive molecules (6).

One of the most important anticarcinogenic phytochemicals contained in cruciferous vegetables of the Brassica genus, such as cabbage, broccoli. Considerable evidence shows that indole-3-carbinol (I3C) inhibits experimentally induced tumorigenesis at different sites in the colon, lung, skin, liver, cervix, and mammary gland in mouse and rat models (7). Hence, the current study was undertaken to evaluate the gastroprotective effects of indole-3-carbinol against AA-induced gastric ulcers in rats and the effect of acidified AA and indole-3-carbinol treatment on histological staining, and on antioxidant status of gastric tissue homogenate, they were assessed by determining glutathione activity levels.

The present study was aimed to evaluate the antiulcerogenic effect of indole-3-carbinol as a new safer anti-inflammatory and antioxidant activities

compound found in cruciferous vegetables against AA-induced gastric mucosal damage on various experimental ulcer models.

Materials and Methods:

Drugs:

1. Acetylsalicylic acid (AA) (Bayer AG, Germany). Acetylsalicylic acid was given to animals in this study at a dose of 500 mg/kg body weight (8).

2. Omeprazole (OMP). In this study, omeprazole was used as the reference antiulcer drug and was obtained from the pharmacy. Omeprazole was administered orally to rats in concentrations of 20 mg/kg body weight according to the recommendation of Giri *et al.*, (9).

3. Indole-3-carbinol (I3C). drug was purchased from Sigma-Aldrich Chemical Company U.S.A. (Cairo, Egypt). This drug was administered orally to rats in concentrations of 50 mg/kg body weight (10). All drugs was dissolved in distilled water.

Experimental animals:

Male albino rats were obtained from the animal house. The rats weighed between 200-250g. The animals were housed in polypropylene cages with sterile, inert husk materials as bedding. The experimental animals were maintained under controlled environmental conditions with a temperature ($23\pm 2^{\circ}\text{C}$). They were allowed to acclimatize for 10 days and were provided free access to a standard pellet diet and water ad libitum. Animals were fasted about 24 hours with free access to drinking water before starting the experiment.

Experimental design:

In the present investigation, a total number of 48 male albino rats were used. They were divided into eight experimental groups of six animals in each group.

- 1- Normal control group. Animals were given orally distilled water for 7 days.
- 2- OMP group. Animals were given orally omeprazole 20 mg /kg/b.w . for 7 days.

- 3- I3C group. Animals were given orally indole-3-carbinol 50 mg/kg/b.w. for 7 days.
- 4- OMP+I3C group. Animals were given orally omeprazole 20 mg/kg/b.w.+ indole-3-carbinol 50mg/kg/b.w. for 7 days.
- 5- AA group. Animals were given orally aspirin 500 mg/kg/b.w. for 7 days.
- 6- AA+OMP group. Animals were given orally aspirin 500 mg/kg/b.w. + omeprazole 20 mg/kg/b.w. for 7 days.
- 7- AA+I3C group. Animals were given orally aspirin 500 mg/kg/b.w. + indole-3-carbinol 50 mg/kg/b.w. for 7 days.
- 8- ASA+OMP+I3C group. Animals were given orally aspirin 500 mg/kg/bw + omeprazole 20 mg/kg/b.w. + indole-3-carbinol 50 mg/kg/b.w. for 7 days.

Gross Gastric Lesions Evaluation:

Ulcers of the gastric mucosa appear as elongated bands of black hemorrhagic lesions parallel to the long axis of the stomach. The gastric mucosa of each rat was thus examined for damage. The length and width of the ulcer (mm) were measured by a planimeter ($10 \times 10 \text{mm}^2 = \text{ulcer index}$) under dissecting microscope (1.8x). The ulcerated index was measured by counting the number of small squares, $2 \text{mm} \times 2 \text{mm}$, covering the length and width of each ulcer band. The sum of the index of all lesions for each stomach was applied in the calculation of the ulcer index (UI) where in the sum of small squares $\times 4 \times 1.8 = \text{UI (mm}^2)$ according to the recommendation of Mahmood *et al.*, (11). Evaluation of the degree of ulceration was expressed in terms of ulcer score by :

Ulcer score = (Total number of ulcers in a group)/(Number of rats in a group)

The percentage of ulceration was calculated by the following formula according to the recommendation of Mahmood *et al.*, (12).

$$(\text{I}\%) = [(\text{UI control} - \text{UI treated}) \div \text{UI control}] \times 100\%.$$

Histopathological evaluation of gastric lesions:

Specimens of the gastric walls of each rat were fixed in 10% buffered formalin and processed in a paraffin tissue processing machine. Sections of the stomach were made at a thickness of 5μ and stained with hematoxylin and eosin for histological evaluation (13).

Statistical analysis:

Statistical analysis was performed using the statistical package for social science (SPSS) version 17.0 statistical analysis package. Parameters were analyzed using significance by one-way analysis of variance (ANOVA) followed by Dennett's T3 multiple comparison test significance levels were analyzed at $p < 0.05$.

Results:

Ulcer index, percentage of ulceration, and ulcer score:

Table 1. was represented ulcer index, ulcer score, and percentage of ulceration in the control group, and treated groups at seven days. No ulcers were detected in the stomach of control-treated groups, and normal control. Whereas, acetylsalicylic acid administration caused an increase in the mean values of ulcer index, ulcer score, and percentage of ulceration in rats' stomachs after seven days when compared with omeprazole, and indole-3-carbinol groups.

Table (1): Averages of ulcer index, ulcer score, and percentage of ulceration in control and experimental groups at seven days.

Groups	Ulcer index	Percentage of ulceration	Ulcer score
	Mean \pm SE	Mean \pm SE	Mean \pm SE
Normal control	0.00	0.00	0.00
OMP control (20mg/kg)	0.00	0.00	0.00
I3C control (50mg/kg)	0.00	0.00	0.00
OMP+ I3C (20+50mg/kg)	0.00	0.00	0.00
AA (500mg/kg)	2.40 \pm 0.87**	71.28 \pm 0.14**	1.67 \pm 0.71**
OMP(20mg/kg) + AA (500mg/kg)	0.12 \pm 0.01*	4.02 \pm 0.003*	0.004 \pm 0.00*
I3C (50mg/kg) + AA (500mg/kg)	0.00	0.00	0.00
OMP+ I3C (20+50mg/kg) + AA(500mg/kg)	0.00	0.00	0.00

Significant value at $P < 0.05$. * (Significant). ** (Highly Significant).

Histopathological results:

Omeprazole and indole-3-carbinol groups alone/ or with others showed normal gastric mucosal tissue with no ulcer compared with normal control (figs.1, 2, 3, and 4). Histological examination of gastric mucosal tissue of AA group (fig.5) showed sharply defined ulcer crater at the site of exposure to AA almost reaching the submucosal layer, discontinuity of lining epithelium, and deep oedema covering the total glandular epithelium with damage in the mucosal epithelium and leukocytic infiltration. Moreover, mild hyperplasia and mild oedematous submucosa with some leucocytic infiltration were recognized in omeprazole treated ulcerated rats, also showed discontinuation of the epithelial lining with diffuse lymphocytic infiltration extending into the submucosa, submucosal oedema, loss of mucosal architecture, and the tendency of exfoliation of gastric pits (fig.6).

On the contrary indole-3-carbinol treatment to ulcerated AA rats alone (fig.7) showed nearly normal mucosa structure with an absence of ulcer crater, clearance of necrosis with few oedema, and maintenance of mucosal layers along with normal glands. While fig.(8) showing few histological lesions in omeprazole with an indole-3-carbinol ulcerated group.

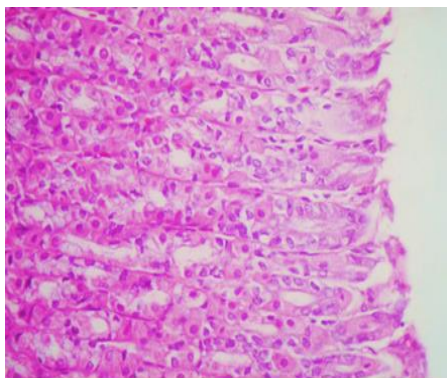


Figure 1: Section of the stomach in control group showing normal histological structure. (H&E, x400).

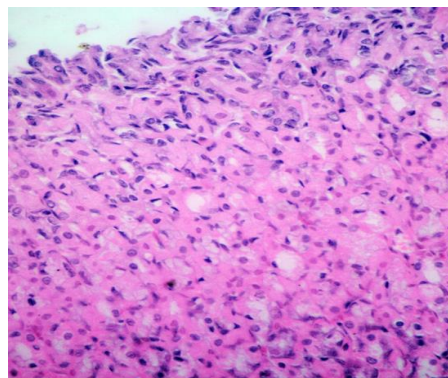


Figure 2: Section of stomach control rat receiving OMP at a dose of (20 mg/kg body weight for 7 days) showing, normal different stomach layers (H&E, x400).

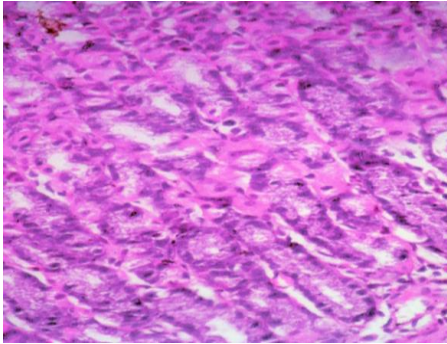


Figure 3: Section of stomach control a rat receiving I3C at a dose of (50 mg/kg body weight) for 7 days showing, the normal pattern of different stomach layers (H&E, x400).

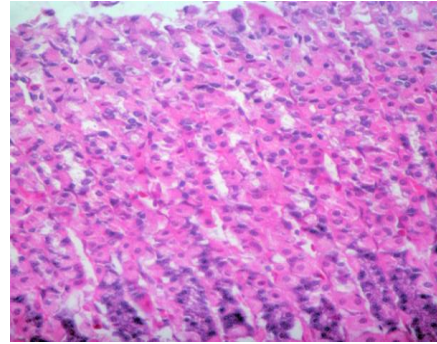


Figure 4: Section of stomach control a rat receiving OMP at a dose of (20 mg/kg body weight) + I3C at a dose of (50 mg/kg body weight) showing, normal pattern gastric tissue (H&E, x400).

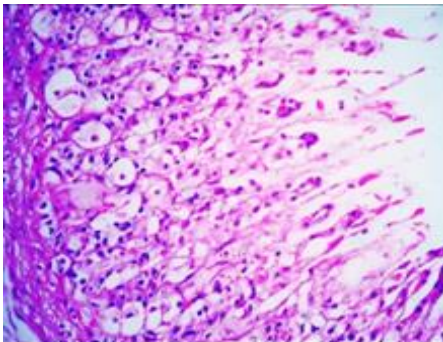


Figure 5:Section of stomach treated with AA at a dose of 500 mg/kg body weight for 7 days showing multiple erosions, oedema and gastric ulceration appeared as saucer-shaped areas of necrosis affecting the mucosa layer with the destruction of the glandular tissue (H&E, x400).

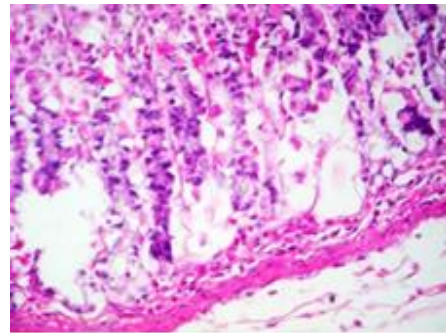


Figure 6:Section of stomach treated with OMP at a dose of (20 mg/kg body weight) + AA at a dose of (500 mg/kg body weight) for 7 days showing vacuolated cytoplasm, dilatation of the glandular luminae and haemorrhagic lesions in the mucosa of glandular stomach "Ulceration at the mid part of the mucosa" (H&E, x400).

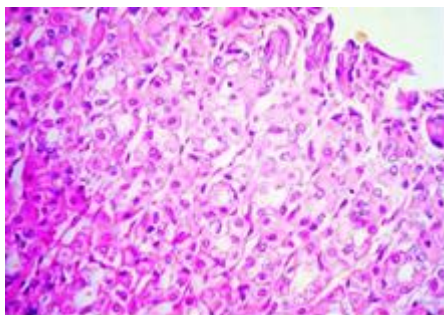


Figure 7:Section of stomach treated with I3C at a dose of (50 mg/kg body weight) + AA at a dose of (500 mg/kg body weight) for 7 days nearly normal mucosa structure with the absence of ulcer crater, clearance of necrosis with few oedema (H&E, x400).

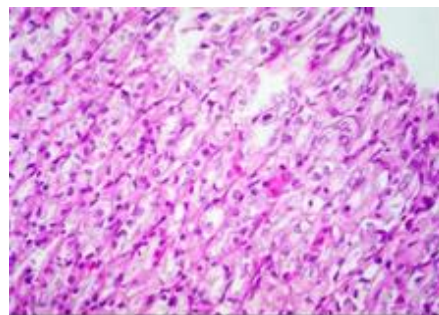


Figure 8:Section of stomach treated with OMP at a dose of (20 mg/kg body weight) + I3C at a dose of (50 mg/kg body weight) + AA at a dose of (500 mg/kg body weight) for 7 days showing few histological lesions (H&E, x400).

Discussion:

Peptic ulcers are caused by an imbalance between the protective and the aggressive mechanisms of the mucosa and are the result of the association of several endogenous factors and aggressive exogenous factors that are related to living conditions (14). AA-induced gastric lesions impaired gastric defensive factors such as mucus and mucosa circulation. Acetylsalicylic acid causes necrotic lesions of the gastric mucosa in a multifactorial way. It can reach the mucosa by disruption of the mucus-bicarbonate barrier and cause cell rupture in the wall of blood vessels (15). These effects are probably due to biological actions, such as lipid peroxidation, formation of free radicals, intracellular oxidative stress, changes in permeability and depolarization of the mitochondrial membrane before cell death (15). In addition, it produces linear hemorrhagic lesions, extensive submucosal oedema, mucosal friability, inflammatory cells infiltration, and epithelial cell loss in the stomach, which are typical characteristics of acetylsalicylic acid injury (16). Mucous secretion is regarded as a crucial defensive factor in the protection of the gastric mucosa from gastric lesions (17). In the present study, the histological examination of gastric mucosal tissue of the AA group revealed sharply damaged mucosal epithelium reaching the submucosal layer with haemorrhage, discontinuity of lining epithelium. These consequences may be related to the back-diffusion of

acid into the mucosa which directly leads to vascular leakage and aggressive damaging effect in the basement membrane of both epithelial and mucosal cells in the gastric wall (18). Histopathology results of the present study also revealed protection of gastric mucosa and inhibition of leucocytes infiltration of the gastric wall in rats pretreated with indole-3-carbinol. Similarly, El-Shinnawy et al., demonstrated that the reduction of neutrophil infiltration into ulcerated gastric tissue promotes the prevention of gastric ulcers in rats (19). Alshailabi showed that oral administration of indole-3-carbinol with acetylsalicylic acid administration significantly decreased neutrophil infiltration of the gastric mucosa (20). The ulcer prevention or healing by indole-3-carbinol was associated with an increase in the mucus layer in the gastric mucosa and protecting the inflammatory cytokine-mediated oxidative damage to gastric mucosa (21). The experimental results of the study showed that indole-3-carbinol has an effective antisecretory and antiulcer activity against ASA-induced gastric mucosal injury. Indole-3-carbinol decreased the acidity and increased the gastric wall mucus. Similarly, Mahmood et al. discovered a reduction in gastric acidity in treated animals. Oxygen-free radicals derived from infiltrated neutrophils in ulcerated gastric tissues have an inhibitory effect on gastric ulcers healing in rats (22). Neutrophils are a major source of inflammatory mediators and can release potent reactive oxygen species such as superoxide, hydrogen peroxide, and myeloperoxidase derived oxidants as a result they mediate lipid peroxidation (23). These reactive oxygen species are highly cytotoxic and can induce tissue damage (24). The anti-inflammatory activity could also be a key factor in the prevention of gastric ulcers as reported by Swarnakar et al., (25). Indole-3-carbinol is a naturally occurring hydrolysis product of glucobrassicin found in vegetables of the Cruciferae family. Epidemiological studies suggest that a high dietary intake of cruciferous vegetables is associated with lower cancer risk (26). Thus, the antiulcerogenic activity of indole-3-carbinol may involve its beneficial effect on both offensive and defensive gastric mucosal factors (19). In addition, indole-3-carbinol can inhibit chemically induced neoplasia in the forestomach by selective beneficial alteration of phase I cytochrome P-450 and induction of phase II detoxification enzymes (27). In addition, indole-3-carbinol has been shown to have protective effects due to its oligomerization under acidic conditions and thus, it has been suggested that the observed biological activity may be attributable mainly to these acid condensation products (28). Oxidative stress plays important role in the pathogenesis of various diseases including gastric ulcers, with antioxidants

being reported to play a significant role in the protection of gastric mucosa against various necrotic agents (4). Antioxidants could help to protect cells from damage caused by oxidative stress and enhanced the body's defense systems against degenerative diseases. Administration of antioxidants inhibits AA-induced gastric injury in the rat (29). Indole-3-carbinol play a protective role against gastric ulcer. Its antiulcer effect is related to increased secretion of adherent mucus and pH of gastric content, which may inhibit the generation of oxygen-derived free radicals.

Conclusion:

In this study, it was found demonstrated that treatment of indole-3-carbinol decreased the risk of AA-induced gastric mucosal injury in rats. Moreover, combining indole-3-carbinol with omeprazole in the treatment of gastric ulcers is potentially a new approach for decreasing gastrointestinal injury caused by AA and other NSAIDs.

References:

1. A. S. AlRashdi *et al.*, Mechanisms of gastroprotective effects of ethanolic leaf extract of *Jasminum sambac* against HCl/ethanol-induced gastric mucosal injury in rats. *Evidence-Based Complementary and Alternative Medicine* **2012**, (2012).
2. J.-i. Choi *et al.*, Effect of fucoidan on aspirin-induced stomach ulceration in rats. *Chemico-Biological Interactions* **183**, 249 (2010).
3. K. K. Abdul-Aziz, Comparative evaluation of the anti-ulcer activity of curcumin and omeprazole during the acute phase of gastric ulcer. *Food Nut Sci* **2**, 628 (2011).
4. D. Bardi *et al.*, Anti-ulcerogenic activity of *Typhonium flagelliforme* aqueous leaf extract against ethanol-induced gastric mucosal injury in rats. *Scientific Research and Essays* **6**, 3232 (2011).
5. K. S. de Lira Mota *et al.*, Flavonoids with gastroprotective activity. *Molecules* **14**, 979 (2009).
6. G. Schmeda-Hirschmann, E. Yesilada, Traditional medicine and gastroprotective crude drugs. *Journal of ethnopharmacology* **100**, 61 (2005).
7. T. Melkamu, X. Zhang, J. Tan, Y. Zeng, F. Kassie, Alteration of microRNA expression in vinyl carbamate-induced mouse lung tumors and modulation by the chemopreventive agent indole-3-carbinol. *Carcinogenesis* **31**, 252 (2010).
8. S. Sarkar, D. Guha, Effect of ripe fruit pulp extract of *Cucurbita pepo* Linn. in aspirin induced gastric and duodenal ulcer in rats. (2008).

9. M. A. Giri, R. D. Bhalke, S. C. Pal, Gastroprotective effect of hydroalcoholic leaves extract of *Pongamia pinnata*. *International Journal of Pharma and Bio Sciences* **1**, 1 (2010).
10. J. A. Crowell, J. G. Page, B. S. Levine, M. J. Tomlinson, C. D. Hebert, Indole-3-carbinol, but not its major digestive product 3, 3'-diindolylmethane, induces reversible hepatocyte hypertrophy and cytochromes P450. *Toxicology and applied pharmacology* **211**, 115 (2006).
11. A. Mahmood, F. Al-Bayaty, I. Salmah, N. S. AB, H. Harita, Enhancement of gastric ulcer by *Areca catechu* nut in ethanol-induced gastric mucosal injuries in rats. *Journal of Medicinal Plants Research* **5**, 2462 (2011).
12. A. Mahmood, A. A. Mariod, F. Al-Bayaty, S. I. Abdel-Wahab, Anti-ulcerogenic activity of *Gynura procumbens* leaf extract against experimentally-induced gastric lesions in rats. *Journal of Medicinal Plants Research* **4**, 685 (2010).
13. R. D. Lillie, *Histopathologic technic and practical histochemistry*. (The Blakiston, 1954).
14. S. Demir *et al.*, Role of free radicals in peptic ulcer and gastritis. *Turkish Journal of Gastroenterology* **14**, 39 (2003).
15. M. Sannomiya *et al.*, Flavonoids and antiulcerogenic activity from *Byrsonima crassa* leaves extracts. *Journal of Ethnopharmacology* **97**, 1 (2005).
16. W. Jelski, M. Kozlowski, J. Laudanski, J. Niklinski, M. Szmikowski, The activity of class I, II, III, and IV alcohol dehydrogenase (ADH) isoenzymes and aldehyde dehydrogenase (ALDH) in esophageal cancer. *Digestive diseases and sciences* **54**, 725 (2009).
17. F. Oluwole, J. Ayo, B. Omoloso, B. Emikpe, J. Adesanwo, Methanolic extract of *Tetracera potatoria*, an antiulcer agent increases gastric mucus secretion and endogenous antioxidants. *Nigerian Journal of Physiological Sciences* **23**, (2008).
18. M. Jainu, K. V. Mohan, C. S. Devi, Gastroprotective effect of *Cissus quadrangularis* extract in rats with experimentally induced ulcer. *Indian Journal of Medical Research* **123**, 799 (2006).
19. N. A. El-Shinnawy, S. A. Abd-Elmageid, E. M. Alshailabi, Evaluation of antiulcer activity of indole-3-carbinol and/or omeprazole on aspirin-induced gastric ulcer in rats. *Toxicology and industrial health* **30**, 357 (2014).
20. E. M. Alshailabi, Effects of omeprazole on healing of non-steroidal anti-inflammatory drug (NSAID)-induced peptic ulceration in rats and protective role of indole-3-carbinol. *Arstjour.* **12**, 1 (2016).
21. C.-C. Chang *et al.*, Deformity of duodenal bulb, gastric metaplasia of duodenal regenerating mucosa and recurrence of duodenal ulcer: a

- correlated study. *World Journal of Gastroenterology: WJG* **11**, 1802 (2005).
22. A. Mahmood, K. Sidik, H. Fouad, Prevention of ethanol-induced gastric mucosal injury by *Ocimum basilicum* seed extract in rats. *ASM Science Journal* **1**, 1 (2007).
 23. H. Kobayashi *et al.*, Quality control of reactive oxygen species measurement by luminol-dependent chemiluminescence assay. *Journal of andrology* **22**, 568 (2001).
 24. C. Cheng, M. Koo, Effects of *Centella asiatica* on ethanol induced gastric mucosal lesions in rats. *Life sciences* **67**, 2647 (2000).
 25. S. Swarnakar, A. Mishra, K. Ganguly, A. V. Sharma, Matrix metalloproteinase-9 activity and expression is reduced by melatonin during prevention of ethanol-induced gastric ulcer in mice. *Journal of pineal research* **43**, 56 (2007).
 26. D. T. Verhoeven, H. Verhagen, R. A. Goldbohm, P. A. van den Brandt, G. van Poppel, A review of mechanisms underlying anticarcinogenicity by brassica vegetables. *Chemico-biological interactions* **103**, 79 (1997).
 27. Y. Zhang, Cancer-preventive isothiocyanates: measurement of human exposure and mechanism of action. *Mutation Research/Fundamental and Molecular Mechanisms of Mutagenesis* **555**, 173 (2004).
 28. K. R. Grose, L. F. Bjeldanes, Oligomerization of indole-3-carbinol in aqueous acid. *Chemical research in toxicology* **5**, 188 (1992).
 29. R. Sathish, A. Sahu, K. Natarajan, Antiulcer and antioxidant activity of ethanolic extract of *Passiflora foetida* L. *Indian journal of pharmacology* **43**, 336 (2011).

التأثير الوقائي للإندول-3-كاربينول على إصابة المعدة في الجرذان

عيدة مفتاح عبدالكريم الشيلابي

قسم علم الحيوان, كلية العلوم, جامعة عمر المختار, البيضاء, ليبيا.

الملخص العربي

ان الهدف من هذا البحث هو معرفة التأثير الوقائي للإندول-3-كاربينول ضد إصابة المعدة التي يسببها حمض أسيتيل الساليسيليك. تم تقسيم ذكور الجرذان بشكل عشوائي إلى ثماني مجموعات, ستة حيوانات في كل مجموعة. مجموعة تحكم و مجموعة أومبيرازول ومجموعة الاندول-3-كاربينول ومجموعة أومبيرازول واندول-3-كاربينول معا. تم إعطاء الماء المقطر للجرذان الضابطة عن طريق الفم, وتم إعطاء الجرذان التجريبية الأخرى عن طريق الفم حمض أسيتيل الساليسيليك بجرعة 500 مجم/كجم من وزن الجسم، أومبيرازول بجرعة 20 مجم/كجم من وزن الجسم، والإندول-3-كاربينول عند جرعة 50 مجم/كجم من وزن الجسم إما بمفردها أو مع بعضها البعض، مرة واحدة لمدة سبعة أيام متتالية. أظهرت نتائج الدراسة الحالية أن الإندول-3-كاربينول قام بحماية غشاء المعدة من القرحة من خلال الحفاظ على الشكل الطبيعي لنسيج المعدة، والتي تضمنت تقليل حجم فوهة القرحة واستعادة النسيج الطلاني المخاطي للمعدة. لذلك فإن الإندول-3-كاربينول أظهر تأثيرا وقائيا ضد قرحة المعدة.

الكلمات المفتاحية: هيستوباثولوجي، المعدة، حمض أسيتيل الساليسيليك، إندول-3-كاربينول،

جرذان.